

CASE REPORT

Prolactinoma Presenting with Secondary Amenorrhoea in a Young Girl

HALIMA HANA AK^{1,2}, LEELAVATHI M², KATIMAN E³, AZIZ NA²

¹Ministry of Health Malaysia, Pusat Pentadbiran Kerajaan Persekutuan, 62000 Putrajaya, Malaysia

²Department of Family Medicine, Faculty of Medicine, Universiti Kebangsaan Malaysia, Jalan Yaacob Latif, Bandar Tun Razak, 56000 Cheras, Kuala Lumpur, Malaysia

³Medical Department, Hospital Kajang, Jalan Semenyih, 43000 Kajang, Selangor, Malaysia

Received: 18 May 2023 / Accepted: 13 July 2023

ABSTRAK

Prolaktinoma merupakan adenoma pituitari yang paling lazim dijumpai. Presentasi klinikal pada lelaki dan wanita adalah berbeza mengikut umur. Wanita muda lazimnya mengalami masalah kitaran haid, ketidaksuburan dan "galactorrhoea" manakala lelaki dan wanita warga emas lazimnya mengalami kekurangan libido, gangguan penglihatan dan sekiranya lambat dikesan, mungkin mengalami komplikasi seperti osteoporosis. Punca putus haid melebihi tempoh tiga bulan di kalangan wanita yang sebelumnya mempunyai kitaran haid yang normal perlu disiasat kerana ia mungkin disebabkan oleh kehamilan, masalah hypothalamus, masalah kelenjar pituitary atau Sindrom Polycystic Ovarian (PCOS). Prolaktinoma dapat disahkan apabila tahap prolaktin dalam darah adalah tinggi dan adenoma dikesan pada pengimejan resonans magnetik (MRI) kelenjar pituitari. Ubat dopaminergik agonis seperti cabergoline amat berkesan untuk menurunkan tahap prolaktin kembali ke paras normal dan membolehkan fungsi gonad dan seksual pesakit kembali seperti sediakala. Kami membentangkan laporan kes mengenai seorang gadis berusia 18 tahun yang mengalami masalah kitaran haid yang tidak teratur. Tahap prolaktin yang tinggi, 466.9 ng/mL (tahap normal: 4.0- 23) serta MRI pituitari yang menunjukkan tumor berukuran 1.2 x 1.1 x 1.4 cm, mengesahkan bahawa pesakit mengalami masalah makroprolaktinoma. Selepas enam bulan rawatan dengan ubat cabergoline, kitaran haid dan tahap prolaktin pesakit telah kembali normal. MRI pituitari pula menunjukkan pengurangan saiz ketumbuhan selepas setahun menerima rawatan.

Address for correspondence and reprint requests: Assoc. Prof. Dr. Leelavathi Muthupalaniappen. Department of Family Medicine, Faculty of Medicine, Universiti Kebangsaan Malaysia, Jalan Yaacob Latif, Bandar Tun Razak, 56000 Cheras, Kuala Lumpur, Malaysia. Tel: +603-9145 9475 Email: drleelaraj@gmail.com

Kata kunci: Adenoma pituitari; amenoria; galaktoria; prolaktinoma

ABSTRACT

Prolactinoma is the most common secreting pituitary adenoma. It has different clinical presentation in men and women which varies with age. Young women present with menstrual problems, infertility and galactorrhoea, whilst older women and men may present with loss of libido, visual disturbances and in late cases, with osteoporosis. In approaching a young woman with secondary amenorrhoea, other causes such as pregnancy, functional hypothalamic amenorrhea, pituitary adenoma, Polycystic Ovarian Syndrome (PCOS) or primary ovarian insufficiency should be ruled out. Prolactinoma can be confirmed in the presence of high serum prolactin level and adenoma on pituitary gland magnetic resonance imaging (MRI). Dopaminergic agonist, cabergoline is efficacious in restoring gonadal and sexual functions by normalising prolactin levels. We presented a case report on an 18-year-old girl who presented with secondary amenorrhoea for six months. On further evaluation she was noted to have galactorrhoea with substantially high prolactin level of 466.9 ng/mL (normal range: 4.0- 23) and the MRI showed a pituitary tumour measuring 1.2 x 1.1 x 1.4 cm. A diagnosis of macroprolactinoma was made and she was managed with cabergoline with gradual dose increment. At 6 months of treatment, her menstrual cycle and serum prolactin had normalised. A repeat MRI pituitary one year later showed reduction in tumour size.

Keywords: Amenorrhoea; galactorrhoea; pituitary adenoma; prolactinoma

INTRODUCTION

Pituitary adenoma accounts for about 10% of all intracranial tumours and is usually classified based on the size or the cell of origin. Tumours less than 1 cm are called microadenoma while those which are 1 cm or more, are called macroadenoma. Lesions greater than 4 cm are called "giant" macroadenoma. Pituitary tumours which secrete hormones are called functioning adenomas while those which do not secrete hormones, are called non-functioning adenomas. Functioning adenomas may arise from

any cell of the anterior pituitary gland and cause hypersecretion of hormones such as prolactin, growth hormone (GH), adrenocorticotrophic hormone (ACTH) or thyroid stimulating hormone (TSH) (Synder et al. 2020). Prolactinoma is the commonest functioning pituitary adenoma, accounting for about 53% of these tumours (Daly & Beckers 2020).

Prolactinoma (prolactin-secreting tumour) can occur in both men and women. However, the clinical presentation is different for men, premenopausal, and postmenopausal women. Young, premenopausal women tend to present early

with menstrual disturbances, galactorrhoea and infertility (Martin 2020). Postmenopausal women on the other hand, present late, with reduced libido, visual disturbances due to compression on the optic nerve or with complications such as osteoporosis. Men tend to present with erectile dysfunction and loss of libido. Large and occasionally giant tumours are more common in men and postmenopausal women where they present with compressive features such as bitemporal hemianopia, ophthalmoplegia and headache (Martin 2020). Prolactinoma among women in reproductive age group usually present with menstrual disorders and galactorrhoea (Synder 2020). Galactorrhoea is defined as production of breast milk in the absence of pregnancy or lactation (Gosi & Garla 2023). It is usually bilateral, accompanied with nipple discharge appearing whitish or slightly green. A serosanguinous discharge suggests possible underlying breast pathology and should prompt further investigation to exclude possible breast malignancy. Other rare manifestations of prolactinomas include recurrent epistaxis and glaucoma (Karl et al. 2015; Li et al. 2023)

Prolactinoma responds well to oral dopamine agonists such as bromocriptine and cabergoline, providing symptomatic relief, stabilisation of biochemical parameters, thus rarely requiring surgical intervention. We presented a case report of a young girl who presented with secondary amenorrhoea and on further evaluation was noted to have

galactorrhoea. She was diagnosed to have macroprolactinoma based on symptoms, blood investigation and imaging results. The patient was successfully managed with dopamine agonist. A review of this condition with the latest treatment modalities are also discussed in this case report.

CASE REPORT

An 18-year-old girl complained of irregular menstrual cycle for three months, then became amenorrhoeic for six months. She attained menarche at the age of 12 years and her menses had been regular since then. On further questioning, she admitted to having spontaneous whitish yellow breast discharge bilaterally for almost one year. There was no bloody discharge, pain or any lumps in either breast. She also experienced intermittent throbbing headaches for the past two months which was worsened in the evenings. However, there were no visual problems, weakness, or numbness of any limbs. She was nulliparous and was not on any drugs.

Clinically, she presented with normal body habitus and a body mass index of 22.8 kg/m². Breast examination showed bilateral non-expressive galactorrhoea. There were no breast lumps, lymph nodes and the overlying skin was normal. Cervical and axillary lymph nodes were not palpable. There was no acne, hirsutism, skin pigmentation or acanthosis nigricans. Cranial nerve, eye and visual field examinations were normal. All other system examination was unremarkable. The combined presentation of amenorrhoea,

galactorrhoea and headache led to the possible diagnosis of prolactinoma.

Preliminary investigation to rule out pregnancy, as a cause for secondary amenorrhoea and galactorrhoea in her was negative. Evaluation of pituitary hormones showed high serum prolactin on consecutive testing, with a level of 466.9 & 467 ng/mL (normal range: 4.0-23). Other pituitary hormones such as follicular stimulating hormone (FSH), luteinizing hormone (LH), TSH, serum oestradiol and progesterone were all within normal range. Her full blood count, lipid profile, renal and liver function tests were also normal. Pituitary gland magnetic resonance imaging (MRI) showed a left suprasellar mass measuring 1.2 x 1.1 x 1.4 cm (Transverse x Craniocaudal x Anterior Posterior). The floor of the sella was thin, and the mass protruded into the sphenoid sinus. Superiorly there was no extension to the floor of the 3rd ventricle or optic chiasm. There was minimal extension of the mass into the

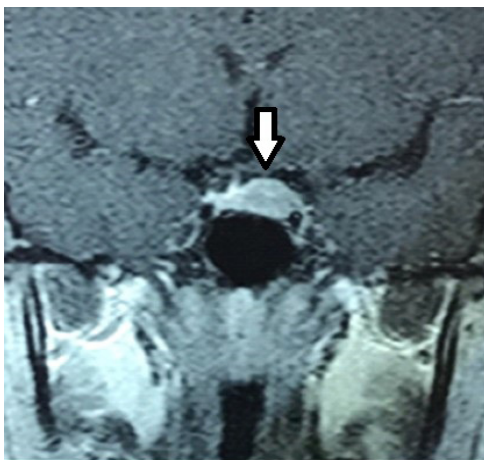

FIGURE 1: Pituitary gland MRI at diagnosis showed a suprasellar mass (arrow)

left cavernous sinus internal carotid artery (ICA). Right cavernous sinus and right cavernous ICA were not involved (Figure 1). In summary, based on the history of amenorrhoea, galactorrhoea, headache and investigations showing persistently high serum prolactin level and pituitary tumour on MRI findings, the final diagnosis of a functioning pituitary macroadenoma with hyperprolactinemia (macroprolactinoma) was confirmed.

The patient was started on treatment with cabergoline 0.25 mg twice a week on Mondays and Thursdays in the first two weeks. The dose was further stepped up to 0.5mg biweekly on weeks three and four. She was reviewed at the fourth week of treatment where she felt better with less frequent headaches and nipple discharge. She experienced minimal side effects of cabergoline, which was nausea but there was no abdominal pain, change in mood or behaviour. Her prolactin level had reduced slightly to 433.3 ng/mL. Subsequently, the cabergoline dose was increased by 0.5mg until she was on maintenance dose of 1mg twice a week. After 6 months of treatment, her menses became regular and there was no more galactorrhoea. Her prolactin level had reduced to 25.9 ng/mL (normal range: 4-23) and a repeat MRI at one year, showed that the tumour had reduced in size (1.0 x 1.1 x 1.0 cm) and appeared less dense (Figure 2).

DISCUSSION

Prolactinoma is a benign tumour which presents with symptoms of hormonal

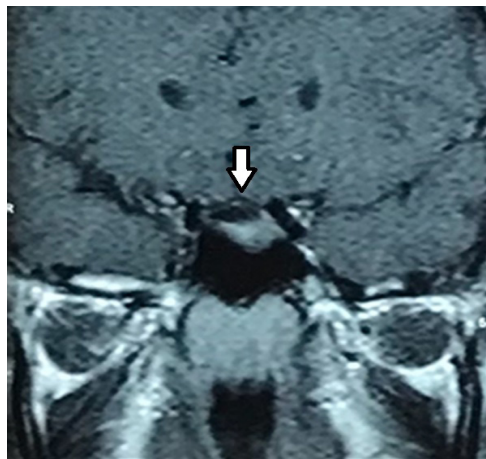


FIGURE 2: At 1-year post treatment, the MRI showed reduction in the suprasellar mass size (arrow)

excess or deficiency, neurological symptoms secondary to mass effect or may be asymptomatic (Lake et al. 2013). The symptoms may be different among different age groups and gender. Our patient presented with secondary amenorrhoea and headache. Secondary amenorrhoea is defined as absence of menses for more than three months in a woman who previously had regular menstrual cycles or six months in those who had irregular menses. The general approach to secondary amenorrhoea is to first, rule out pregnancy. Other possible causes which need to be ruled out are stress, eating disorder, exercise, polycystic ovarian syndrome (PCOS), primary ovarian insufficiency, certain drugs such as metoclopramide or antipsychotic drugs and pituitary tumour (Welt et al. 2023).

The causes of galactorrhoea are divided into hypothalamic-pituitary and non-hypothalamic-pituitary causes of increased prolactin

production. The most common hypothalamic-pituitary cause is due to an underlying prolactinoma. Almost 90% of premenopausal women with hyperprolactinemia, present with galactorrhoea (Huang & Molitch 2012). The non-hypothalamic-pituitary causes include hypothyroidism, renal failure, chest wall lesion and certain medications such as antipsychotics and antidepressants (Gosi & Garla 2023). The presence of amenorrhoea and galactorrhoea together is highly suggestive of prolactinoma.

Important physical assessment in these cases includes a clinical breast examination to rule out any breast pathology. Visual field assessment should also be done to look for any defect as patients may be unaware of it in early stages, especially when the better eye compensates for the visual defect. It has been reported that visual field deficit was detected in 10% of incidentally identified pituitary tumours (Lake et al. 2013). If the diagnosis of prolactinoma is delayed, compression at the optic chiasm may cause visual field defects such as bitemporal hemianopia. Compression of the III, IV and VI cranial nerves may result in ophthalmoplegia and headaches (Martin 2020). Patients may also present with fragility fracture as a complication of osteoporosis due to the effect of hypogonadism (Martin 2020).

The standard investigation of suspected prolactinoma is to assess serum prolactin, which would show a persistently high level. This is followed by imaging with pituitary MRI which is the gold standard for diagnosis of

prolactinoma by which the pituitary tumour can be detected (Cozzi et al. 2022).

The main aim of treatment in prolactinoma is to reverse the symptoms of hyperprolactinemia and relieve compression caused by the tumour. The first line treatment is with dopamine agonists and the drug of choice is cabergoline. Most tumours respond well, achieving about 80% reduction in tumour size and serum prolactin with minimal side effects e.g. nausea & vomiting (Petersenn & Giustina 2020).

For microprolactinoma (tumours less than 1 cm), cabergoline is initiated at 0.25 mg twice a week dosage, given in the evening after food to reduce gastrointestinal side effects of the drug and stepped up to 0.5 mg twice a week. Serum prolactin level should normalise within 6 to 8 weeks of treatment (Inder & Jang 2022). If the prolactin level remains high, dosage can be increased to 1mg twice weekly. If serum prolactin does not return to normal level with the 1mg biweekly dosage, then the condition is defined as resistant prolactinoma and cabergoline may be titrated up to 6 mg biweekly (Inder & Jang 2022). For lesions causing a visual defect, cabergoline dose may be stepped more rapidly to 1 mg twice a week by the second week of treatment and symptom improvement may be noted after two weeks of treatment. Most patients with microprolactinoma are treated for about two years from the time of achieving normal serum prolactin levels before cabergoline is withdrawn. However, a recent guideline recommends that for

microprolactinoma, cabergoline may be stopped at menopause for women while men may need to continue the treatment for lifetime. For macroprolactinoma, cabergoline may be required for lifetime, to prevent recurrence. The prognosis for most of the prolactinoma with medical treatment is good with about 60% of microadenomas remaining either the same size or shrink hence frequent monitoring with MRI is unnecessary. (Hordejuk et al. 2023)

Generally, surgical resection of pituitary tumour is rarely required as the response to medical treatment is good. Hence, surgery reserved for patients who are unable to tolerate dopamine agonist or in cases of resistant or recurrent prolactinomas. The chances of recurrence of prolactinoma upon withdrawal of dopaminergic agents is about 2% (Zou et al. 2021). Rise in prolactin levels commonly occurs after about three months (range between 12 to 18 months) of cabergoline withdrawal. In less than 10% of cases, the tumour increases in size post drug withdrawal and causes recurrence of symptoms. Although this patient had reducing levels of prolactin with medication, case reports of aggressive tumours which failed to respond to dopaminergic agonist and requiring multiple surgeries and chemotherapy or radiotherapy have been reported (Borhan & Tan 2022; Pérez Pinzón et al. 2019). A recent systematic review also stated that surgery is an important therapeutic modality for medically failed prolactinoma management. About 38% of patients who failed medical treatment and received

surgical management achieved complete remission and did not require any additional treatment up to about four years of follow up. The remaining 62% were in remission with additional treatment modalities. However, among those who underwent surgery, less than half of them required further treatment with dopaminergic agonist during post-surgery follow-up (Yagnik et al. 2021).

Besides treatment with cabergoline and surgery, there are other modalities of treatment such as radio and chemotherapy. Newer drugs such as temozolomide, tyrosine kinase inhibitors, peptide receptor radionuclide, immunotherapy, hormonal and cytotoxic drugs are currently being studied and may be available in the near future as a treatment option for aggressive tumours (Auriemma et al. 2023).

CONCLUSION

Prolactinoma should be considered as a diagnosis among women presenting with menstrual issues and galactorrhoea after ruling out other common diagnoses. Prolactinoma is the most common pituitary adenoma and it responds well to medical treatment with cabergoline. Hence, early identification and treatment is beneficial to reverse the symptoms. This case report depicted how the diagnosis of prolactinoma was made in a young girl and was successfully managed with medication.

REFERENCES

- Auriemma, R.S., Pirchio, R., Pivonello, C., Garifalos, F., Colao, A., Pivonello, R. 2023. Approach to the patient with prolactinoma. *J Clin Endocrinol Metab* **108**(9): 2400-23.
- Borhan, M.K., Tan, F.H.S. 2022. Aggressive giant prolactinoma: A case report. *J Med Case Rep* **16**(1): 170.
- Cozzi, R., Ambrosio, M.R., Attanasio, R., et al. 2022. Italian association of clinical endocrinologists (AME) and international chapter of clinical endocrinology (ICCE). Position statement for clinical practice: Prolactin-secreting tumors. *Eur J Endocrinol* **186**(3): P1-33.
- Daly, A.F., Beckers, A. 2020. The epidemiology of pituitary adenomas. *Endocrinol Metab Clin North Am* **49**(3): 347-55.
- Gosi, S.K.Y., Garla, V.V. Galactorrhea. 2023. In StatPearls Publishing; <https://www.ncbi.nlm.nih.gov/books/NBK537115/> [April 2023]
- Hordejuk, D., Cheung, Y.M., Wang, W., Smith, T., Laws, E., Kaiser, U.B., Min, L. 2023. Long-term changes in the size of pituitary microadenomas. *Ann Intern Med* **176**(3): 298-302.
- Huang, W., Molitch, M.E. 2012. Evaluation and management of galactorrhea. *Am Fam Physician* **85**(11): 1073-80.
- Inder, W.J., Jang, C. 2022. Treatment of prolactinoma. *Medicina (Kaunas)* **58**(8): 1095.
- Karl, D., Gillan, S.N., Goudie, C., Sanders, R. 2015. Giant prolactinoma mimicking low-tension glaucoma at presentation. *BMJ Case Rep* 2015: bcr2014207634.
- Lake, M.G., Krook, L.S., Cruz, S.V. 2013. Pituitary adenomas: An overview. *Am Fam Physician* **88**(5): 319-27.
- Li, D., Wang, Y., Tan, H., Luo, P., Yu, Y. 2023. A giant invasive macroprolactinoma with recurrent nasal bleeding as the first clinical presentation: Case report and review of literature. *BMC Endocr Disord* **23**(1): 107.
- Martin, N. 2020. Prolactinoma, BMJ Best Practice. <https://bestpractice.bmj.com/search?q=prolactinoma> [May 2021]
- Petersenn, S., Giustina, A. 2020. Diagnosis and management of prolactinomas: Current challenges. *Pituitary* **23**(1): 1-2.
- Pérez Pinzón, J., González-Devía, D., Kattah Calderón, W., López Panqueva, R.D.P., Jiménez Hakim, E. 2019. Unusual course of an aggressive pituitary prolactinoma: Case report and review of the literature. *Case Rep Neurol* **11**(1): 148-56.
- Synder, P., Cooper, D.S., Martin, K.A. 2020. Causes, presentation, and evaluation of sellar masses – UpToDate. <https://medilib.ir/uptodate/show/6632> [May 2021]
- Welt, C.K., Barbieri, R.L., Crowley, W.F., Geffner, M.E., Martin, K.A. 2023. Evaluation and

management of secondary amenorrhea. <https://www.ncbi.nlm.nih.gov/books/NBK279144/> [April 2023]

- Yagnik, K.J., Erickson, D., Bancos, I., Atkinson, J.L. D., Choby, G., Peris-Celda, M., Van Gompel, J.J. 2021. Surgical outcomes of medically failed prolactinomas: A systematic review and meta-analysis. *Pituitary* **24**(6): 978-88.
- Zou, Y., Li, D., Gu, J., Chen, S., Wen, X., Dong, J., Jiang, X. 2021. The recurrence of prolactinoma after withdrawal of dopamine agonist: A systematic review and meta-analysis. *BMC Endocr Disord* **21**(1): 225.