

CASE REPORT

Primary Mucinous Carcinoma of the Axillary Skin: A Case Report & The Role of Adjuvant Tamoxifen

NUR FA'IZAH A, FUAD I

Department of Radiotherapy & Oncology, Faculty of Medicine, Universiti Kebangsaan Malaysia, Jalan Yaacob Latif, Bandar Tun Razak, 56000 Cheras, Kuala Lumpur, Malaysia

Received: 08 Nov 2023 / Accepted: 12 Dec 2023

ABSTRAK

Kanser kulit primer jenis berlendir (KKPB) adalah kanser yang jarang berlaku. Ia sejenis kanser yang lambat membiak dan berkembang dengan perlahan tetapi boleh berulang secara lokal, merosakkan struktur setempat. Majoriti kanser berlendir yang berlaku pada kulit adalah kanser metastatik yang berasal dari organ yang lain. Melihat dari sudut morfologi, KKPB hampir tidak dapat dibezakan daripada deposit metastatik sekunder. Kami melaporkan kes seorang lelaki yang berusia 44 tahun, dengan kes KKPB di bahagian kulit ketiak kiri yang telah merebak ke kelenjar limfa setempat. Ketepatan diagnosis patologi adalah mencabar tetapi ia telah dibantu oleh beberapa pakar patologi dari pusat yang berbeza. Satu mesyuarat pelbagai disiplin menyimpulkan bahawa pendekatan pengurusan terbaik adalah dengan melakukan pembedahan dengan margin sekitar yang luas dan membuang kelenjar limfa di ketiak secara total, diikuti oleh terapi adjuvan tamoxifen. Peranan terapi adjuvan radioterapi juga telah disarankan tetapi ditolak oleh pesakit. Kini setelah 22 bulan sejak mula disahkan mengalami KKPB, pesakit dilaporkan sihat tanpa tanda kanser berulang.

Kata kunci: Estrogen; indolen; kanser kulit ganjil; metastasis kulit sekunder

ABSTRACT

Primary mucinous carcinoma of the skin (PMCS) is a rare cancer. It is indolent and progresses slowly but can recur locally, damaging the structure. The majority of mucinous carcinoma that occurs in the skin are metastatic lesions originating from various sites. In terms of morphology, PMCS is almost indistinguishable from secondary metastatic deposits. We reported a case of a 44-year-old male with

Address for correspondence and reprint requests: Nur Fa'izah Binti Ab Muin. Department of Radiotherapy & Oncology, Faculty of Medicine, Universiti Kebangsaan Malaysia, Jalan Yaacob Latif, Bandar Tun Razak, 56000 Cheras, Kuala Lumpur, Malaysia. Tel: +6011-28388054 Email: drfaizah_abmuin@ukm.edu.my

left axillary skin PMCS that had spread to axillary lymph nodes. The pathologic diagnosis was challenging but was facilitated by expert pathologists from different centers. A multidisciplinary meeting concluded that the best management approach was to include a wide local excision and axillary clearance followed by adjuvant tamoxifen. The role of adjuvant radiotherapy was discussed but was declined by the patient. The patient is well now with no recurrence, 22 months since the diagnosis.

Keywords: Indolent; oestrogen; rare skin cancer; skin metastasis

INTRODUCTION

Primary mucinous carcinoma of the skin (PMCS) is an uncommon cancer. It is a very low grade malignancy of the eccrine sweat glands (Martinez & Young 2004). PMCS most commonly occur at the eyelid, followed by the face, scalp, axilla, chest and foot (Karimipour et al. 1997; Mendoza & Helwig 1971; Pilgrim et al. 1985; Rao et al. 1978; Wright & Font 1979). It is indolent and progresses slowly (Adefusika et al. 2015). Although PMCS is rare to spread to regional lymph nodes and often has good prognosis, it can sometimes recur locally and damage the local structure (Miller & Maloney 1998; Pilgrim et al. 1985; Requena et al. 1997).

CASE REPORT

A 44-year-old male with no known medical illness was initially diagnosed with small bowel neuroendocrine tumour pT3N2M0. There was an incidental finding left axillary lesion on the computed tomography (CT) scan that had no uptake on the positron emission tomography Gallium-68 dotatate (dotatate) scan. This finding

triggered a further investigation to look out for second primary cancer.

The patient presented initially with intestinal obstruction in December 2021. CT scan of the abdomen in December 2021 showed enhancing mass at the mid-ileum measuring 7.8 x 3.2 x 3.1 cm. He had exploratory laparotomy and small bowel resection. Histopathological evaluation showed a neuroendocrine tumour, grade 1, with transmural infiltration into the subserosa layer; lymphovascular and perineural invasion were positive, clear margin with Ki67 <3%, and 13/30 lymph nodes were positive. Immunohistochemical staining showed positive for CKAE1/AE3, synaptophysin and chromogranin.

Postoperatively, he had a CT thorax in December 2021 that showed the left axillary lymphadenopathy, left skin lesion and small left breast nodule (Figure 1). However, the dotatate scan in January 2022 showed no definite somatostatin receptor-expressing lesion, even though there were enlarged matted left axillary nodes. These findings rose the suspicion of second primary cancer.

Further history gathered from the

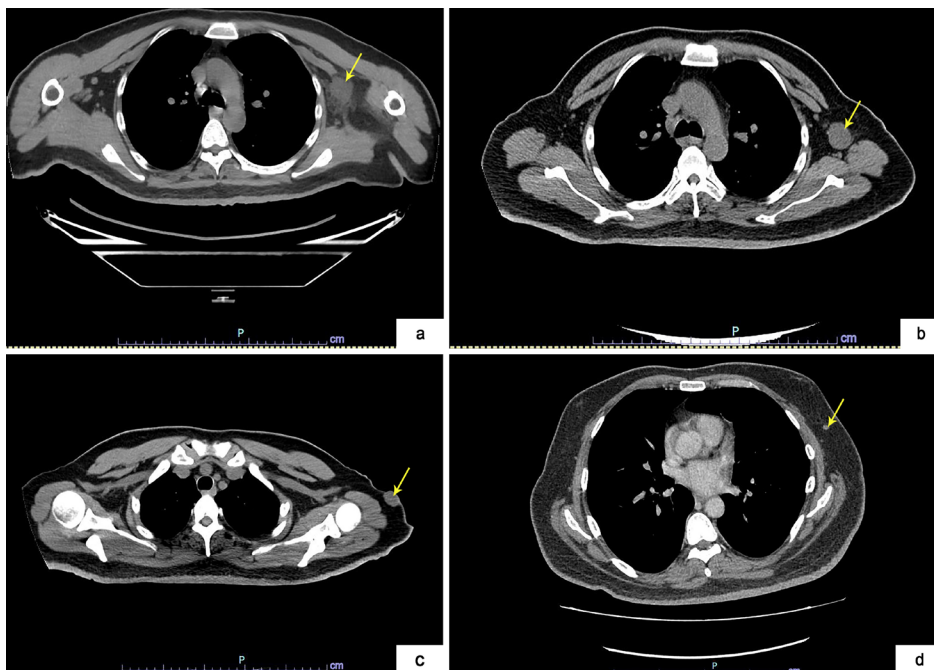


FIGURE 1: CT images showed lesions at (a) Left axillary node; (b) Left axillary node; (c) left axillary skin lesion (d) Small left breast nodule

patient revealed the presence of a left axillary skin wart for four years, which started to have some discharge in October 2021, coincidentally after the COVID-19 vaccination. Subsequent imaging was done to rule out a second primary of breast cancer. A mammogram, ultrasound, and magnetic resonance imaging (MRI) of the breast and axilla showed left axillary nodes, with the largest nodes measuring 2.4 x 5.2 cm; however, there was no breast lesion.

He underwent left axilla skin and nodal excision in January 2022. Histopathological evaluation of the excised left axilla skin lesion revealed adenocarcinoma with mucinous differentiation. It was positive for oestrogen receptor (ER), progesterone receptor (PR), GATA binding protein

3 (GATA 3) and mammaglobin. The left axilla node revealed a metastatic mucinous adenocarcinoma in two out of six lymph nodes. The tamoxifen was started in March 2022, given the ER's positivity.

Multiple inputs and second opinions from different pathologists were sought to confirm the diagnosis of either PMCS or primary breast mucinous adenocarcinoma. Multidisciplinary discussions were held, and the consensus was to treat the disease as PMCS with regional lymph node metastasis. Axillary clearance was agreed upon, and tamoxifen was continued, given the ER positivity status. Axillary clearance was performed in June 2022. Histopathological evaluation revealed no malignancy out of 20 removed lymph nodes. Options

of adjuvant radiotherapy to the axilla were discussed, given the initial presentation with an ulcerated skin lesion and node positivity. The patient, however, declined radiotherapy over close surveillance.

The patient was continued on active surveillance for the small bowel neuroendocrine tumour. His latest dotatate scan in May 2023 showed no evidence of recurrence. As for the axilla PMCS, he was planned for five years of adjuvant tamoxifen and he had close surveillance with ultrasound. He is well now, 22 months since the diagnosis. His latest follow-up ultrasound of the axilla in July 2023 showed no evidence of axillary lymphadenopathy.

DISCUSSION

The majority of mucinous carcinoma that occurs in the skin are metastatic lesions originating from various sites including the breast, gastrointestinal, renal pelvis, ovary, salivary glands, lacrimal glands, paranasal sinuses, and lung (Coady et al. 1989; Requena et al. 1997). Therefore, it is crucial to differentiate between PMCS from metastatic carcinoma to ensure proper management. Performing a thorough oncological evaluation via physical examination and radiological scan is crucial to rule out the non-cutaneous primary malignant site. Detailed histological and pathological characteristics of the mucinous lesion will subsequently guide the proper diagnosis.

Breast and colon cancer can have about 19% and 6% probability of metastasis to the skin and thus can

mimic PMCS (Coan et al. 2012; Ohnishi et al. 2002). In terms of morphology, PMCS is almost indistinguishable from secondary metastatic deposits (Levy et al. 2010). Immunohistochemical staining for CK20 (Bettedini et al. 2015) and CDX2 can facilitate the differentiation of PMCS from secondary deposits from the colon as it usually will be positive in the colon and negative for PCMC. On the contrary, it is less helpful in distinguishing PMCS from metastatic deposits from mucinous adenocarcinoma of the breast as both tumours will be positive for cytokeratin 7 (CK7) (Levy et al. 2010) GATA 3 (Mertens et al. 2015) mammaglobin, ERs and PR (Levy et al. 2010). The myoepithelial component in the tumour could support PMCS; however, this is less commonly found (Adefusika et al. 2015; Levy et al. 2010).

In our case, after discussing with different pathologist experts, it was concluded that the morphology and immunohistochemistry did little to help distinguish PMCS from metastatic deposit to skin from breast; however, the in-situ component was not observed in the specimen.

Surgical resections with adequate margin remain the mainstay of treatment for PMCS (Martinez & Young 2004; Pilgrim et al. 1985; Snow & Reizner 1992). Regional lymph node metastasis is rare; thus, surgery for the draining lymph nodes is not routine and only removed if the disease has spread clinically (Kavitha et al. 2019; Pilgrim et al. 1985). Radiotherapy and chemotherapy were reported to play little role in this tumour (Pilgrim et al. 1985; Yeung & Stinson 1977).

The expression of oestrogen and progesterone in PMCS has been reported and brings the potential therapeutic target with anti-oestrogen, e.g. tamoxifen, that may reduce the recurrence rate (Breiting et al. 2008; Carson et al. 1995; Hanby et al. 1998; Kwatra et al. 2005). Adjuvant tamoxifen exhibited promising results, contributing to a complete and stable remission for three years for a patient with scalp eccrine adenocarcinoma with locoregional recurrence that had undergone complete resection (Schröder et al. 2004). Furthermore, in the metastatic context, tamoxifen showed efficacy, exemplified by two cases demonstrating complete regression of lymph node metastasis (Daniel et al. 2001; Sridhar et al. 1989). Notably, one patient achieved complete remission of lymph nodes, experienced improved bone metastasis-related pain, and sustained a progression-free survival (PFS) for three years (Sridhar et al. 1989). The second patient remained disease-free for more than three years (Daniel et al. 2001). Additionally, anastrozole demonstrated durable remission in metastatic PMCS with an eleven-month progression-free survival in a case of PMCS with lung metastasis (Miyachi et al. 2018) and five years progression free survival in another case of unresectable scalp PMCS (Shockman et al. 2014). In the absence of data and randomised clinical trials, the treatment for eccrine carcinoma must be customised to each patient's unique circumstances.

In the present case, the first operation removed the left axilla skin lesion and

nodal excision. Due to metastasis to the lymph nodes, a follow-up axillary clearance surgery was performed. The presence of an ulcerated skin lesion and the node positivity were considered high-risk features for local recurrence. Therefore, adjuvant radiotherapy was offered even though it was reported to play little role in this tumour. The tamoxifen was also initiated as an adjuvant treatment, given the ER positivity of the tumour supported by the previous report in the literature.

CONCLUSION

Given the rarity of this tumour, the knowledge regarding effective management, particularly adjuvant treatment, is still scarce. Surgery is the mainstay of treatment; however, the role of lymph node clearance, adjuvant radiotherapy and endocrine therapy is debatable. In our case, we have treated the patient with adequate local excision and axillary clearance, followed by endocrine therapy which was planned for five years. The patient is currently well on adjuvant tamoxifen, with no evidence of recurrence on surveillance, 22 months since the diagnosis.

REFERENCES

- Adefusika, J.A., Pimentel, J.D., Chavan, R.N., Brewer, J.D. 2015. Primary mucinous carcinoma of the skin: The Mayo Clinic experience over the past 2 decades. *Dermatol Surg* **41**(2): 201-8.
- Bettedini, O.S., Sheikh, S., Shareefi, F., Shahab, R. 2015. Primary mucinous adenocarcinoma of the scalp: A case report and literature review. *Int J Surg Case Rep* **10**: 241-4.
- Breiting, L., Christensen, L., Dahlstrøm, K., Breiting, V., Winther, J.F. 2008. Primary mucinous

- carcinoma of the skin: A population-based study. *Int J Dermatol* 47(3): 242-5.
- Carson, H.J., Gattuso, P., Raslan, W.F., Reddy, V. 1995. Mucinous carcinoma of the eyelid. An immunohistochemical study. *Am J Dermatopathol* 17(5): 494-8.
- Coady, A.T., Shousha, S., Dawson, P.M., Moss, M., James, K.R., Bull, T.B. 1989. Mucinous carcinoma of the breast: Further characterization of its three subtypes. *Histopathology* 15(6): 617-26.
- Coan, E.B., Doan, A., Allen, C. 2012. Mucinous eccrine carcinoma: a rare case of recurrence with lacrimal gland extension. *Ophthalmic Plast Reconstr Surg* 28(5): e109-110.
- Daniel S.J., Nader R., Kost K., Huttner I. 2001. Facial sweat gland carcinoma metastasizing to neck nodes: a diagnostic and therapeutic challenge. *Arch Otolaryngol Head Neck Surg* 127: 1495-8.
- Hanby, A.M., McKee, P., Jeffrey, M., Grayson, W., Dublin, E., Poulosom, R., Maguire, B. 1998. Primary mucinous carcinomas of the skin express TFF1, TFF3, estrogen receptor, and progesterone receptors. *Am J Surg Pathol* 22(9): 1125-31.
- Karimipour, D.J., Johnson, T.M., Kang, S., Wang, T.S., Lowe, L. 1997. Mucinous carcinoma of the skin. *J Am Acad Dermatol* 36(2 Pt 2): 323-26.
- Kavitha, A., Kavya, C., Sneha, K., Teja, C. 2019. Primary mucinous carcinoma of skin with a trichoadenomatous component: A rare case report. *Indian J Dermatol Venereol Leprol* 85(2): 171-4.
- Kwatra, K.S., Prabhakar, B.R., Jain, S. 2005. Oestrogen and progesterone receptors in primary mucinous carcinoma of skin. *Australas J Dermatol*, 46(4): 246-9.
- Levy, G., Finkelstein, A., McNiff, J.M. 2010. Immunohistochemical techniques to compare primary vs. metastatic mucinous carcinoma of the skin. *J Cutan Pathol* 37(4): 411-5.
- Martinez, S.R., Young, S.E. 2004. Primary mucinous carcinoma of the skin: A review. *Internet J Oncol* 2(2): 1-7
- Mendoza, S., Helwig, E.B. 1971. Mucinous (Adenocystic) carcinoma of the skin. *Arch Dermatol* 103(1): 68-78.
- Mertens, R.B., de Peralta-Venturina, M.N., Balzer, B. L., Frishberg, D.P. 2015. GATA3 Expression in normal skin and in benign and malignant epidermal and cutaneous adnexal neoplasms. *Am J Dermatopathol* 37(12): 885-91.
- Miller, S.J., Maloney, M.E. 1998. Cutaneous oncology : Pathophysiology, diagnosis, and management. Malden: Blackwell Science.
- Miyachi H., Hashimoto H., Suehiro K., Yamamoto Y., Ota S., Nakatani Y., Matsue H. 2018. Aromatase inhibitor for the treatment of primary mucinous carcinoma of the skin with distant metastasis. *JAAD Case Rep* 4(3): 235-8.
- Ohnishi, T., Takizawa, H., Watanabe, S. 2002. Immunohistochemical analysis of cytokeratin and human milk fat globulin expression in mucinous carcinoma of the skin. *J Cutan Pathol* 29(1): 38-43.
- Pilgrim, J.P., Kloss, S.G., Wolfish, P.S., Heng, M.C. 1985. Primary mucinous carcinoma of the skin with metastases to the lymph nodes. *Am J Dermatopathol* 7(5): 461-9.
- Rao, K.V., Tikku, I., Kapur, B.M., Chopra, P. 1978. Invasive primary mucinous carcinoma of the skin. *Int Surg* 63(3): 168-70.
- Requena, L., Kiryu, H., Ackerman, A.B. 1997. Neoplasms with apocrine differentiation. Philadelphia: Lippincott Raven.
- Schröder, U., Dries, V., Klussmann J.P., Wittekindt C., Eckel, H.E. 2004. Successful adjuvant tamoxifen therapy for estrogen receptor-positive metastasizing sweat gland adenocarcinoma: Need for a clinical trial? *Ann Otol Rhinol Laryngol* 113(3 Pt 1): 242-4.
- Shockman, S., Krug, L., Lountziz, N. 2014. Remission of metastatic primary mucinous carcinoma of the skin with anastrozole. *J Am Acad Dermatol* 71(1): e27-28.
- Snow, S.N., Reizner, G.T. 1992. Mucinous eccrine carcinoma of the eyelid. *Cancer* 70(8): 2099-104.
- Sridhar K.S., Benedetto P., Otrakji C.L., Charyulu K.K. 1989. Response of eccrine adenocarcinoma to tamoxifen. *Cancer* 64: 366-70.
- Wright, J.D., Font, R.L. 1979. Mucinous sweat gland adenocarcinoma of eyelid: A clinicopathologic study of 21 cases with histochemical and electron microscopic observations. *Cancer* 44(5): 1757-68.
- Yeung, K.Y., Stinson, J.C. 1977. Mucinous (adenocystic) carcinoma of sweat glands with widespread metastasis. Case report with ultrastructural study. *Cancer* 39(6): 2556-62.