

CASE REPORT

Recurrent Chalazia Secondary to Bortezomib

FATIN HANISAH F¹, RONA ASNIDA N², JEMAIMA CH²

¹*Ophthalmology Discipline, Faculty of Medicine, Universiti Teknologi MARA (UiTM),
Jalan Hospital, 47000 Sungai Buloh, Selangor, Malaysia*

²*Department of Ophthalmology, Faculty of Medicine, Universiti Kebangsaan Malaysia
Medical Centre, Jalan Yaacob Latif, Bandar Tun Razak, 56000 Cheras, Kuala Lumpur,
Malaysia*

ABSTRAK

Kes chalazia yang disebabkan oleh bortezomib pernah dilaporkan namun ia bukanlah dikenalpasti sebagai satu kesan sampingan kepada bortezomib. Kami dengan ini melaporkan kes chalazion yang berulang disebabkan rawatan bortezomib. Seorang pesakit lelaki berusia 40 tahun yang menghidap myeloma rantaian ringan telah mengalami chalazia di mata kiri dan meibominitis di kedua-dua belah mata selepas sepuluh minggu menerima rawatan kemoterapi dengan bortezomib. Walaupun dirawat, chalazia pesakit tidak pulih hingga menyebabkan rawatan bortezomib dihentikan. Setelah ubat doxycycline diberi, chalazia pesakit semakin pulih dan rawatan kemoterapi disambung, namun chalazia pesakit berulang kembali dan memerlukan incision & curettage. Rawatan dengan azithromycin telah mengecutkan chalazia pesakit tanpa perlu menghentikan kemoterapi. Hubungan antara bortezomib dan chalazia telah dicirikan sebagai reaksi ubat yang berkemungkinan menurut klasifikasi World Health Organization, dan pengiktirafannya sebagai reaksi ubat akan membolehkan pengenalan awal dan pengurusan bersama pesakit dengan pakar onkologi.

Kata kunci: bortezomib, chalazia, kesan sampingan, PS-341, Velcade

ABSTRACT

Few cases of chalazia secondary to bortezomib are reported in literature. However, it is not a recognized ocular adverse effect. We hereby report a case of recurrent chalazia secondary to bortezomib. A 40-year-old male with light chain myeloma on ten weeks of chemotherapy with bortezomib was treated for left eye inflamed

Address for correspondence and reprint requests: Associate Professor Dr. Jemaima Che Hamzah. Department of Ophthalmology, Faculty of Medicine, Universiti Kebangsaan Malaysia Medical Centre, Jalan Yaacob Latif, Bandar Tun Razak, 56000 Cheras, Kuala Lumpur, Malaysia. Tel: +603-91455981/5982 Email: jemaima@ppukm.ukm.edu.my

chalazion with bilateral meibominitis. Severe chalazia persisted despite treatment, which necessitated cessation of chemotherapy. The patient's condition improved on oral doxycycline and chemotherapy was recommenced but his chalazia recurred, necessitating incision and curettage. His chalazia responded to oral azithromycin without further cessation of chemotherapy. Bortezomib's association with chalazia has been characterized as a possible adverse drug reaction according to the World Health organization classification, and its recognition as an established adverse reaction to will allow earlier identification and appropriate co-management of the patient.

Keywords: bortezomib, chalazia, meibomian cyst, PS-341, Velcade

INTRODUCTION

Chalazia refers to a localized benign lipogranulomatous inflammation involving the meibomian glands. Chalazia are usually diagnosed clinically, although in atypical presentation, histopathological diagnosis may be obtained (Özdal et al. 2004). Bortezomib, also known as Velcade or PS-341, is a proteasome inhibitor derived from boron. Bortezomib inhibits the threonine residue of the 26S proteasome, which is an enzyme complex that regulates protein degradation (Field-Smith et al. 2006). It is used in the treatment of multiple myeloma including its variant, light chain myeloma.

Few cases of chalazia secondary to bortezomib are reported in literature. However, it is not a recognized ocular adverse effect of bortezomib. We report a case of recurrent chalazia occurring after the initiation of bortezomib in a patient with light chain myeloma.

CASE REPORT

A 40-year-old male presented to our clinic with left eye upper and lower lid swelling and redness with for 1-week duration. There was no associated redness or eye discharge. He had underlying light chain myeloma, diagnosed six months prior following a pathological fracture of his left clavicle. He was commenced on velcade/cyclophosphamide/dexamethasone (VCD) chemotherapy, consisting of subcutaneous bortezomib 2.1 mg, oral cyclophosphamide 500 mg and oral dexamethasone 40 mg. While being reviewed, he was on his third cycle of weekly chemotherapy, each cycle consisting of four weeks.

On examination, his visual acuity was 6/9, pinhole 6/6 N6 OS. He had multiple swelling over his left upper and lower eyelids. His conjunctiva was not injected, and cornea was clear. Intraocular pressure and fundus examination was normal. He was diagnosed with left eye inflamed chalazion with bilateral meibominitis (Figure 1). He was started on topical oxytetracycline twice daily and warm fomentation.

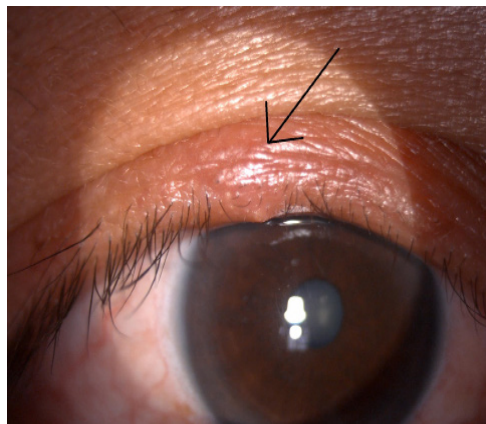


Figure 1: Chalazion over the upper eyelid (depicted by arrow).

He developed further swelling despite compliance to treatment, and his chemotherapy was stopped 10 days later by the treating haematologist. On review, he had thick, viscous secretions from his meibomian glands with multiple inflamed chalazia (Figure 2). Oral doxycycline 100 mg twice daily was commenced. He had epigastric discomfort due to the oral doxycycline but completed a 1-month course.

His lid lesions appeared less inflamed and he underwent incision and curettage of his left eye upper lid chalazion 2 weeks later. As his condition improved, he was treated with repeat third cycle of VCD chemotherapy. He subsequently developed new chalazia over bilateral upper and lower lids, and his vision deteriorated to 6/18 OD, due to astigmatism induced by his upper lid chalazia. He received oral azithromycin 500mg daily. No reduction, alteration or cessation of chemotherapy occurred. When we reviewed at 2 weeks of his fifth chemotherapy cycle, his vision was 6/9 OS with multiple small non-inflamed

chalazia.

DISCUSSION

Multiple myeloma is a haematological malignancy of B-cell lymphoproliferation. B-cells produce antibodies, consisting of 2 heavy chains and 2 light chains. The heavy chains are IgG, IgA, IgM, IgD and IgE, and the light chains are kappa and lambda. In 15% of multiple myeloma cases, exclusive proliferation of light chains occur, termed light chain myeloma (Zhang et al. 2014).

Bortezomib is a proteasome inhibitor derived from boron. It inhibits the threonine residue of the 26S proteasome, which is an enzyme complex that regulates

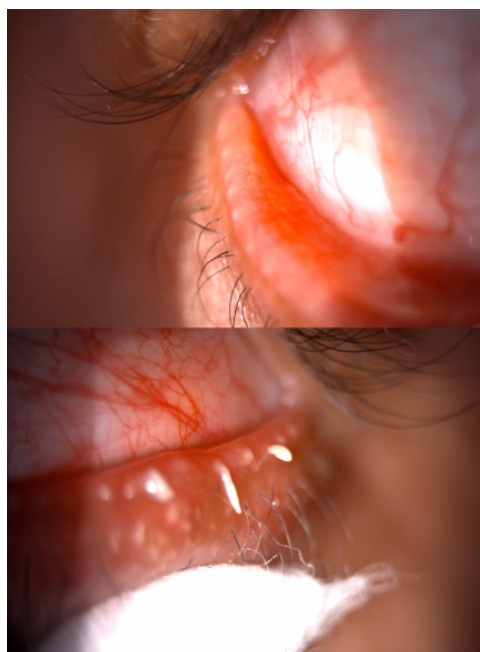

Figure 2: a) Inflamed and capped meibomian glands along lower lid margin; b) Thick, viscous meibomian gland secretions after manual expression of glands with sterile cotton bud

protein degradation. Proteosomes are present in all eukaryotic cells. Proteins are tagged with ubiquitin, which directs them to the proteasome, which subsequently degrades the protein. Inhibition of the proteasome causes a buildup of proteins leading to cell death. Proteasome inhibition is reversible upon cessation of treatment hence normal cells can usually recover but malignant cells are more sensitive. Bortezomib is shown to increase survival rates in light chain myeloma (Zhang et al. 2014).

Adverse reactions to bortezomib include gastrointestinal symptoms, fatigue, thrombocytopenia and neutropenia. The US Food and Drug Administration (FDA) has listed minor ocular adverse events in relation to bortezomib use, including diplopia, blurred vision, conjunctival infection and irritation (Fu et al. 2017). Neuropathy is a severe adverse reaction, in some cases necessitating interruption of treatment regimes, reduction of dose and discontinuation of treatment. The SUMMIT study showed bortezomib-related adverse events led to discontinuation of therapy in 18% of patients, however no data from this study showed chalazia as a potential side effect of bortezomib (Richardson et al. 2003). Bortezomib can cause the cutaneous lesions such as leucocytoclastic vasculitis (Agterof & Biesma 2005). Blepharitis following treatment with bortezomib was also reported (Veys et al. 2016).

Chalazion, also known as a meibomian cyst, is a benign lipogranulomatous lesion arising from the meibomian glands in the tarsal plate of the upper

and lower lids. Inspissation of lipids in the gland occurs, which then ruptures. This releases lipids from the gland into the tissue, forming a granulomatous inflammatory reaction. Patients usually complain of a swelling near the eyelid margin with no surrounding oedema or erythema. In few cases, eyelid swelling, redness and tenderness may occur. As in this patient, large chalazion can cause mechanical ptosis and induce astigmatism. Extramedullary plasmacytomas secondary to multiple myeloma may also present with eyelid swelling and mechanical ptosis and its diagnosis should be ruled out as it is a poor prognostic indicator of disease (Aimy Mastura et al. 2017).

Chalazia may resolve with conservative management with warm fomentation and lid hygiene, which involves outward massaging of the meibomian glands towards the lid margin to facilitate meibomian gland drainage. In refractory cases, topical or intralesional steroids and oral doxycycline have been used. Incision and curettage of the chalazion is a definitive treatment in suitable cases unresponsive to conservative management.

Chalazia occurring in bortezomib therapy has been reported in literature, however it has not been identified as an adverse effect of the drug (Ghobrial et al. 2010; Mundia et al. 2012). In a large cohort of patients treated with bortezomib, chalazia was noted to occur in 2% of patients (Ganesh et al. 2014). Chalazia occurrence is found to occur with a mean of three months after initiation of Bortezomib (Fraunfelder & Yang 2016). In this

patient, the chalazia occurred after 10 weeks of commencing chemotherapy. Bortezomib-related chalazia have been described as recalcitrant. It has been postulated that pro-inflammatory activity of bortezomib targets the lipids within the meibomian glands, causing chalazia formation.

Commonly, cessation of bortezomib treatment resulted in improvement in chalazia severity (Grob et al. 2014). Commencement of bortezomib after cessation causes recurrence of chalazia (Puri et al. 2014). Chalazia occurring in patients on bortezomib have been known to be severe enough to cause cessation of ongoing chemotherapy cycles (Puri et al. 2014; Yun et al. 2015). In our patient, cessation of the chemotherapy mid-cycle due to severity of chalazia caused a repeat of his third chemotherapy cycle. Consequentially, bortezomib's association with chalazia has been characterized as a possible adverse drug reaction according to the World Health organization classification (Fraunfelder & Yang 2016). Recognition of this adverse reaction to bortezomib will allow earlier identification and appropriate co-management of the patient with the treating oncologist (Allen 2017).

CONCLUSION

Recurrent chalazia are reported to occur in patients treated with Bortezomib for multiple myeloma and its variants; however, it is currently categorized as a possible adverse reaction. With the ongoing use of bortezomib as treatment for multiple myeloma, coupled with increased

recognition of the association between the two, chalazia in bortezomib treatment may be recognized as a rare adverse drug reaction and facilitate holistic management of patient's morbidity.

ACKNOWLEDGEMENT

The authors would like to thank Ms Munira binti Zainal Abidin @ Jaafar and other staff members of the Ophthalmology Clinic in Universiti Kebangsaan Malaysia Medical Centre (UKMMC), for their assistance in this case report. The authors convey their special thanks to the colleagues in the Haematological Unit of Department of Medicine UKMMC, for their cooperative management of this patient.

REFERENCES

- Agterof, M.J., Biesma, D.H. 2005. Bortezomib-induced skin lesions. *N Engl J Med.* 352(24): 2534.
- Aimy Mastura, Z.Y., Othmaliza, O., Khairunisa, A.A., Norshamsiah, M.D. 2017. Good anatomical outcome of orbital plasmacytoma following chemo-radiotherapy. *Med & Health* 12(2): 341-7.
- Allen, R.C. 2017. Molecularly targeted agents in oculoplastic surgery. *Curr Opin Ophthalmol.* 28(5): 485-92.
- Field-Smith, A., Morgan, G.J., Davies, F.E. 2006. Bortezomib in the treatment of multiple myeloma. *Ther Clin Risk Manag* 2(3): 271-9.
- Fraunfelder, F.W., Yang, H.K. 2016. Association between bortezomib therapy and eyelid chalazia. *JAMA Ophthalmology* 134(1): 88-90.
- Fu, C., Gombos, D.S., Lee, J., George, G.C., Hess, K., Whyte, A., Hong, D.S. 2017. Ocular toxicities associated with targeted anticancer agents: an analysis of clinical data with management suggestions. *Oncotarget* 8(35): 58709.
- Ganesh, K., Batlevi, C., Zhang, Z., Hassoun, H., Lendvai, N., Landau, H., Moskowitz, C.H., Caron, P., Motzer, R., Giralt, S.A., Hamlin, P., Lichtman, S.M., Matasar, M.J., Portlock, C.S.,

- Shukla, N., Wasserheit-Lieblich, C., Zelenetz, A.D., Gerecitano, J.F. 2014. Greater total dose and duration of treatment with bortezomib are associated with higher incidence of chalazion and other ocular side effects. *Blood* **124**: 3487.
- Ghobrial, I.M., Hong, F., Padmanabhan, S., Badros, A., Rourke, M., Leduc, R., Chuma, S., Kunsman, J., Warren, D., Harris, B., Sam, A., Anderson, K.C., Richardson, P.G., Treon, S.P., Weller, E., Matous, J. 2010. Phase II trial of weekly bortezomib in combination with rituximab in relapsed or relapsed and refractory Waldenström macroglobulinemia. *J Clin Oncol* **28**(8): 1422-8
- Grob, S.R., Jakobiec, F.A., Rashid, A., Yoon, M.K. 2014. Chalazia associated with bortezomib therapy for multiple myeloma. *Ophthalmology*. **121**(9): 1845-7.
- Mundia, M., Mundia, A.G., Ali, M.F., Ali, S. 2012. Chalazion in multiple myeloma patients treated with bortezomib. *Journal of Clinical Oncology* **30**: e13053.
- Özidal, P.Ç., Codere, F., Callejo, S., Caissie, A., Burnier, M. 2004. Accuracy of the clinical diagnosis of chalazion. *Eye* **18**(2):135-8.
- Puri, S., Joshi, J., Derman, O., Kornblum, N., Verma, A., Braunschweig, I., Battini, R. 2014. Ocular complications of bortezomib therapy in multiple myeloma. *Blood* **124**: 5743.
- Richardson, P.G., Barlogie, B., Berenson, J., Singhal, S., Jagannath, S., Irwin, D., Rajkumar, S.V., Srkalovic, G., Alsina, M., Alexanian, R., Siegel, D., Orlovski, R.Z., Kuter, D., Limentani, S.A., Lee, S., Hideshima, T., Esseltine, D.L., Kauffman, M., Adams, J., Schenkein, D.P., Anderson, K.C. 2003. A phase 2 study of bortezomib in relapsed, refractory myeloma. *N Engl J Med* **348**(26): 2609-17.
- Veys, M.C., Delforge, M., Mombaerts, I. 2016. Treatment with doxycycline for severe bortezomib-associated blepharitis. *Clin Lymphoma Myeloma Leuk* **16**(7): e109-e12.
- Yun, C., Mukhi, N., Kremer, V., Shinder, R., Verma, V., Olcay, B. 2015. Chalazia development in multiple myeloma: a new complication associated with bortezomib therapy. *Hematol Rep* **7**(2): 5729.
- Zhang, J., Sun, W., Huang, Z., Chen, S., Zhong, Y., Hu, Y., An, N., Shen, M., Li, X. 2014. Light chain multiple myeloma, clinic features, responses to therapy and survival in a long-term study. *World J Surg Oncol* **12**(1): 234.

Received: 28 May 2018

Accepted: 15 Oct 2018