

CASE REPORT

Basal Cell Carcinoma Arising from an Epidermal Naevus

FAZARINA M¹, AZAHSYAHRINA A¹, MOONYZA A², LEE BR³

¹Department of Pathology, ²Dermatology Unit, Department of Medicine, Faculty of Medicine, Universiti Kebangsaan Malaysia Medical Centre, Jalan Yaacob Latif, Bandar Tun Razak, 56000 Cheras, Kuala Lumpur, Malaysia.

³Department of Pathology, Faculty of Medicine and Health Sciences, Universiti Putra Malaysia, 43400 UPM Serdang, Selangor Darul Ehsan, Malaysia.

ABSTRAK

Epidermal naevus adalah hamartoma kulit kongenital yang benigna. Kami mengetengahkan kes yang jarang ditemui iaitu epidermis naevus dengan transformasi malignan untuk karsinoma sel basal. Seorang lelaki berusia 79 tahun telah dibiopsi untuk nodul kulit berukuran 2 x 4 cm yang timbul di dalam lesi papular linear berukuran 2 x 4 cm di sebelah kiri lehernya. Nodul itu kemudiannya disahkan sebagai karsinoma sel basal yang timbul daripada epidermal naevus. Mutasi gen PIK3CA mutasi dikaitkan dengan karsinoma sel basal, yang menunjukkan komponen sel karsinoma basal adalah bebas daripada komponen epidermis naevus. Doktor klinikal dan pakar patologi perlu sedar kemungkinan perubahan malignan yang mungkin timbul dalam epidermal naevus.

Kata kunci: karsinoma sel basal, BCC, epidermal naevus

ABSTRACT

Epidermal naevus is a congenital cutaneous hamartoma with a benign course. We highlight a rare case of epidermal naevus with concurrent basal cell carcinoma. A 79-year-old male had a skin biopsy at our centre for an enlarging skin nodule within a linear papular lesion measuring 2 x 4 cm at the left side of his neck, which was later diagnosed as basal cell carcinoma arising from an epidermal naevus. PIK3CA mutation is attributed to basal cell carcinoma which suggests the basal cell carcinoma component is independent of the epidermal naevus component. Clinicians and pathologists must be aware of possible malignant changes that might arise in an epidermal naevus.

Keywords: basal cell carcinoma, BCC, epidermal naevus

Address for correspondence and reprint requests: Fazarina Mohammed. Department of Pathology, Faculty of Medicine, Universiti Kebangsaan Malaysia Medical Centre, Jalan Yaacob Latif, Bandar Tun Razak, 56000 Cheras, Kuala Lumpur, Malaysia. Tel: +603-91459482 Fax: 03-91459485 E-mail: fazarina.m@gmail.com.

* Abstract was presented in Annual Scientific Meeting of College of Pathologists, Kuala Lumpur, Malaysia.

INTRODUCTION

Epidermal naevus is a congenital cutaneous lesion which is composed of epidermal overgrowth. It arises from Blaschko's lines, which corresponds to the patterns of epidermal migration during embryogenesis. Epidermal naevus usually presents as a flat tan linear lesion at the trunk or limbs during infancy or early childhood (Brandling-Bennett & Morel 2010). As the patient ages, the lesion may be thickened and appear warty. Histologically the lesion presents as proliferation of keratinocytes and skin appendages. Epidermal naevus follows a benign course even when left untreated. Medical treatment such as topical calcitriol is prescribed to reduce the thickness of the lesion if necessary (Zvulunov et al. 1997).

Rarely, epidermal naevus may undergo malignant transformation. Basal cell carcinoma arising within epidermal naevus is even more infrequent, as documented by previous case reports. In this report, we highlight a rare case of epidermal naevus with concurrent basal cell carcinoma.

CASE REPORT

A 79-year-old male presented with several papular lesions in a linear distribution at the left side of his neck measuring 2 x 4 cm. The papular lesions had been present since childhood, but later coalesced and gradually enlarged and thickened. Within the past few months the papular lesions were pruritic with contact bleeding and became ulcerated with crust formation (Figure 1). Based on the history and

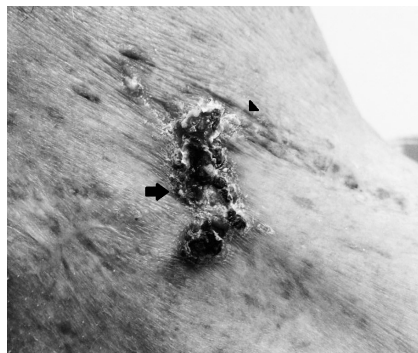

Figure 1: Ulcerated necrotic plaque (arrow) within a papular lesion in a linear distribution (arrowhead) over the left side of patient's neck, with surrounding erythema.

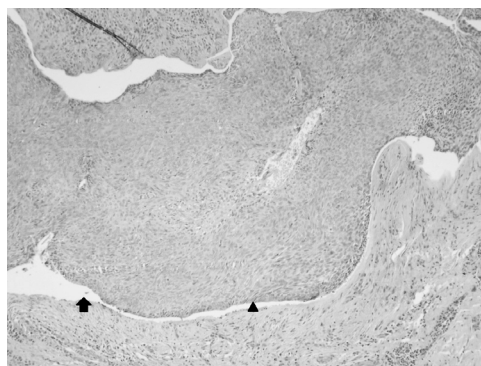


Figure 2: Basaloid malignant cells exhibiting retraction artefact (arrow) and peripheral palisading (arrowhead), H&E, x20 magnification.

clinical examination, the initial clinical impression was linear epidermal naevus with malignant transformation. A skin biopsy was performed to rule out malignancy.

Section from the skin biopsy showed proliferation of basaloid malignant cells arising from the epidermis forming sheets, small nests and trabeculae and infiltrating into the dermis (Figure 2). Peripheral palisading and retraction artefact were also present. These malignant cells were surrounded by parakeratosis, acanthosis and mild

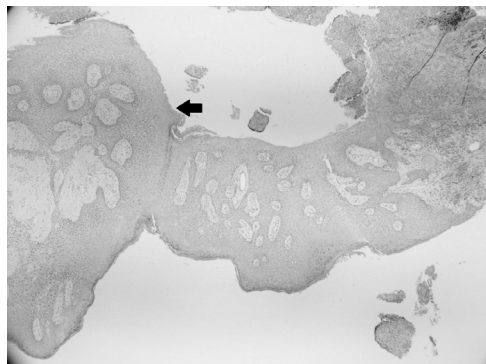


Figure 3: An area of the epidermis exhibiting acanthosis and parakeratosis(arrow), H&E, x4 magnification.

spongiosis of the epidermis, which were consistent with features of epidermal naevus (Figure 3). The diagnosis was finalized as basal cell carcinoma arising from an epidermal naevus.

Further follow-up was scheduled for the patient to monitor for recurrence of the malignancy. However, the patient did not attend further appointment and his outcome was unknown.

DISCUSSION

To date, few cases have been reported regarding this rare entity of basal cell carcinoma in association with epidermal naevus (De et al. 2007; Zheng et al. 2013; Mordovtseva 2015; Viana et al. 2015). Presentation of basal cell carcinoma within an epidermal naevus is similar to classical presentation of basal cell carcinoma of the skin.

Similar to our case, the basal cell carcinoma component may present as an ulcerating foci with rolled edges within the naevus (De et al. 2007; Mordovtseva 2015). The basal cell carcinoma component in an epidermal naevus may also present

as a pearly shiny papule within the epidermal naevus (Viana et al. 2015). Ulceration and shiny papule with rolled edges are classical presentations of basal cell carcinoma. Other than usual examination of the skin lesion, dermoscopy may also be performed.

Dermoscopy is a non-invasive method that can be used to distinguish between the epidermal naevus component and basal cell carcinoma component. Dermoscopy is a skin surface microscopy that can be performed by the dermatologist before doing a biopsy. Different lesions usually produce different patterns on dermoscopy. Verrucous epidermal naevus shows a characteristic appearance of dark brown circles on dermoscopy (Carbotti et al. 2016). Meanwhile, basal cell carcinoma appears hypopigmented on dermoscopy with presence of at least one criterias as listed: blue-gray globules, blue-ovoid nests, maple-leaf like arrangement, arborizing vessels and spoke wheel arrangement (Puig et al. 2012).

Excision of the lesion is the mainstay of treatment for these patients. Based on other case reports, the treatment for basal cell carcinoma in association with epidermal naevus is mainly excision of the entire lesion with adequate skin margin 3 - 5 mm with closure of skin flap if necessary (De et al. 2007; Zheng et al. 2013). All of the cases reported no recurrence during follow-up.

There are different theories on how basal cell carcinoma may arise from epidermal naevus. Malignant transformation of epithelial germ cells within epidermal naevus was thought

to be a possible cause (Crowson 2006). However, a molecular study showed that the basal cell carcinoma component and the epidermal naevus component may be a part of a collision tumour. A collision tumour is the presence of two independent tumours within the same lesion.

A molecular study was done on one lesion of basal cell carcinoma within epidermal naevus to determine whether the epidermal naevus and the basal cell carcinoma components are clonally related (Hafner et al. 2009). The results showed a PIK3CA mutation that was present in the basal cell carcinoma component but not in the epidermal naevus component. This suggests that the basal cell carcinoma component and the epidermal naevus component are a part of collision tumour. However, in view of the limited sample tested for molecular study, the possibility of a relationship between these two entities in the same lesion cannot be excluded. Hence, a more extensive study to include more samples must be done to prove that these two entities are indeed collision tumour.

CONCLUSION

In conclusion, basal cell carcinoma arising from epidermal naevus is a rare occurrence. Despite its benign course, clinicians must be vigilant in observing changes in an epidermal naevus for the possibility of malignancy. Any new lesions within an epidermal naevus should be biopsied. Pathologists must

also be aware of possible malignant lesion within an epidermal naevus. The histology of the lesion must be scrutinized to exclude possibility of malignancy.

REFERENCES

- Brandling-Bennett, H.A., Morel, K.D. 2010. Epidermal nevi. *Pediatr Clin North Am* 57(5): 1177-98.
- Carbotti, M., Coppola, R., Graziano, A., Verona Rinati, M., Paolili, F.L., Zanframundo, S., Panasiti, V. 2016. Dermoscopy of verrucous epidermal nevus: large brown circles as a novel feature for diagnosis. *Int J Dermatol* 55(6): 653-6.
- Crowson, A.N. 2006. Basal cell carcinoma: biology, morphology and clinical implications. 2006. *Mod Pathol* 19 (Suppl 2): S127-47.
- De, D., Kanwar, A.J., Radotra, B.D. 2007. Basal cell carcinoma developing in verrucous epidermal nevus. *Indian J Dermatol Venereol Leprol* 73(2): 127-8.
- Hafner, C., Klein, A., Landthaler, M., Vogt, T. 2009. Clonality of basal cell carcinoma arising in an epidermal nevus: new insights provided by molecular analysis. *Dermatology* 218(3): 278-81.
- Mordovtseva, V. 2015. Multifocal basal cell carcinoma arising within a linear epidermal nevus. 2015. *Indian Dermatol Online J* 6(1): 37-8.
- Puig, S., Cecilia, N., Malveyh, J. 2012. Dermoscopic criteria and basal cell carcinoma. *G Ital Dermatol Venereol* 147(2): 135-40.
- Viana, A., Aguinaga, F., Marinho, F., Rodrigues, R., Cuzzi, T., Ramos-E-Silva, M. 2015. Basal cell carcinoma arising on a verrucous epidermal nevus: a case report. *Case Rep Dermatol* 7(1): 20-4.
- Zheng, L.Q., Huang, Y., Qu, Y.J., Zhang, Y.H., Han, X.C. 2013. Multiple basal cell carcinomas arising in a verrucous epidermal nevus. *J Dermatol* 40(6): 482-3.
- Zvulunov, A., Grunwald, M.H., Halvy, S. 1997. Topical calcipotriol for treatment of inflammatory linear verrucous epidermal nevus. *Arch Dermatol* 133(5): 567-8.

Received: 6 October 2016

Accepted: 17 May 2016