

Villoglandular Papillary Adenocarcinoma of the Uterine Cervix with Lymph Node Metastasis - A Case Report and Review of the Literature

¹Geok Chin Tan, ⁴Mohd Sidik Shiran, ¹Manickam Swaminathan, ¹Md Ali Siti Aishah, ²Poo Ling Ong, ³Mohd Dali Ahmad Zailani Hatta

Department of ¹Pathology, ²Pharmacy, and ³Obstetrics & Gynaecology, Faculty of Medicine, Universiti Kebangsaan Malaysia, Cheras, Kuala Lumpur.

⁴Department of Pathology, Faculty of Medicine, Universiti Putra Malaysia.

ABSTRAK

Adenokarsinoma papilari-villoglandular telah pertama kali dihuraikan oleh Young dan Scully pada tahun 1989 sebagai suatu entiti tersendiri dengan ciri-ciri histologi seperti pertumbuhan eksofitik, struktur vilus dan papilari serta atipia nukleus yang sedikit ke sederhana. Kami melaporkan satu kes adenokarsinoma papilari-villoglandular serviks dengan metastasis ke nodus limfa dan mengkajisemula ciri-ciri klinikopatologi enam kes yang telah dilaporkan. Pesakit ini merupakan kes ketujuh dengan ciri-ciri yang sama seperti kes-kes yang telah dilaporkan. Umur ketujuh-tujuh pesakit adalah diantara 29 hingga 54 tahun (min, 41). Diantara tujuh kes ini, lima mempunyai invasi limfovaskular. Semua kecuali pesakit ketujuh telah dirawat dengan histerektomi radikal dan radioterapi. Jagaan susulan pesakit ketujuh adalah 7 bulan, malangnya beliau telah meninggal dunia akibat infeksi respiratori.

Kata kunci: adenokarsinoma papilari villoglandular, adenokarsinoma, serviks

ABSTRACT

Villoglandular papillary adenocarcinoma was first described by Young and Scully in 1989 as a distinct entity with the histological features of exophytic growth proliferation, villous and papillary architecture and mild to moderate nuclear atypia. We report one case of villoglandular papillary adenocarcinoma (VGPA) of the uterine cervix with lymph node metastasis and reviewed the clinicopathological features of six other cases reported in the literature. Our patient is the seventh similar reported cases. They ranged in age from 29 to 54 (mean, 41) years. Five had lymphovascular invasion. All except our patient were treated with radical hysterectomy and radiotherapy. She was followed-up for 7 months and unfortunately died due to chest infection.

Key words: villoglandular papillary adenocarcinoma, adenocarcinoma, cervix

Address for correspondence and reprint requests: *Dr Tan Geok Chin, Department of Pathology, Faculty of Medicine, Universiti Kebangsaan Malaysia, Jalan Yaacob Latif, Bandar Tun Razak, 56000 Kuala Lumpur. Email: tan_geok_chin@yahoo.com*

INTRODUCTION

Adenocarcinomas account for 10–20% of invasive cervical carcinomas (Young RH et al 1990). Young and Scully (1989) first described a new subset of cervical adenocarcinoma that was designated as “villoglandular papillary adenocarcinoma (VGPA) of the uterine cervix” in 1989. The histological features of VGPA are exophytic growth, papillary architecture and mild to moderate cellular atypia. It has been reported as a distinctive histological subtype which developed in relatively young women (33-52 years old) and has a favourable prognosis (Young RH et al 1989, Hopson L et al 1990, Jones MW et al 1993, Reed W et al 1993, Costa MJ et al 1995). Approximately 80 cases of VGPA have been reported in the literature (Young RH et al 1989, Jones MW et al 1993, Kaku T et al 1997, Stanley-Christian H et al 1997, Khunamrnping S et al 2001). Its incidence has been quoted as 3.7-4.8% of the adenocarcinoma of the cervix (Garcea A et al 2003). There are only six cases of VGPA with lymph node metastasis reported in the literature, of which five showed lymphatic space permeation in the main tumour (Kaku T et al 1997, Utsugi K et al 2002, Khunamrnping S et al 2001, Garcea A et al 2003). We report a case of VGPA with right obturator lymph node metastasis and a review of the six similar cases reported in literature.

CASE REPORT

A 45-year-old multigravid Malay housewife presented with a one week history of generalised abdominal pain, which was intermittent, sharp stabbing in nature and aggravated by inspiration. She had two full term spontaneous vaginal deliveries that were antenatally uneventful. She was a known diabetic and hypertensive on metformin and prazosin for the past eight years. She never had a pap smear done. There was no family history of gynecological malignancy, smoking or

alcohol consumption. There was no history of oral contraceptive usage.

She was pale, and weighed 67 kilograms. Systemic examinations were unremarkable. Cervical examination revealed a nodular exophytic, friable, hemorrhagic growth, arising from the posterior wall of the cervix, measuring 2.0 cm in diameter. A piece of the tissue detached during manipulation. A biopsy was obtained, with the clinical impression of cervical carcinoma stage IB.

Microscopically, the cervical biopsy specimen was composed of fragments of polypoidal tissues with villous and papillary fronds arranged in complex branching pattern. The papillae were lined by glandular epithelium displaying mild to moderate nuclear atypia (Figure 1). Mitotic figure count was brisk (90/10 high power field). Lymphovascular invasion was not present.

She was planned for a Wertheim hysterectomy, however, during the operation, frozen section detected right obturator lymph node metastasis (Figure 2). Wertheim hysterectomy was abandoned due to the advanced disease, instead, a bilateral salpingoophorectomy, myomectomy for leiomyoma and right iliac and obturator lymphadenectomy were performed. She also received 30 doses of external radiotherapy with concurrent chemotherapy of five cycles of weekly cisplatin. Unfortunately she died seven months after the surgery due to chest infection.

A synopsis of the clinicopathological features of villoglandular papillary adenocarcinoma of uterine cervix with lymph node metastasis in the literature

There are approximately 80 cases of VGPA ever reported in the literature. Of these, six cases presented with lymph node metastasis (7.5%). A synopsis of the clinicopathological features of the above six cases together with our present case is listed in table 1. The ages ranged from 29

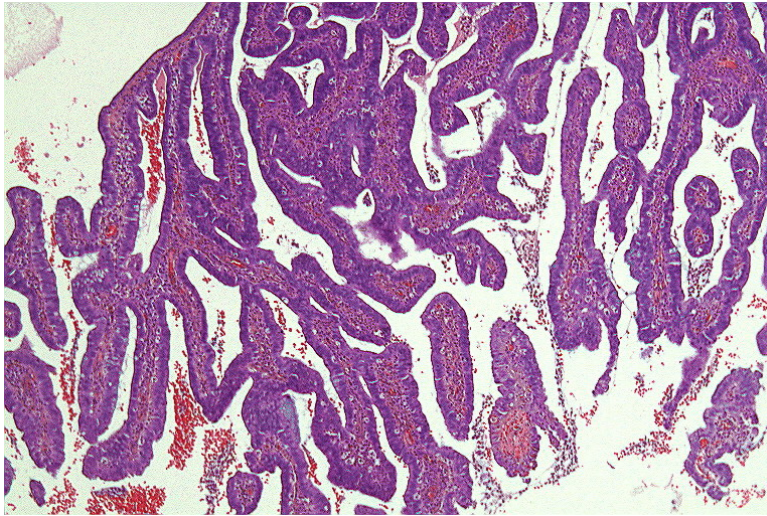


Figure 1: Exophytic tumour composed of villous and papillary architecture (H&E, 10x magnification)

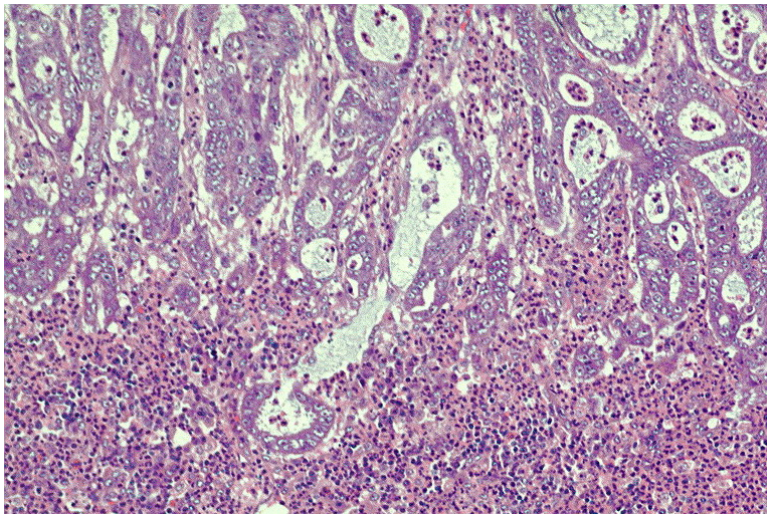


Figure 2. Histological section of the right obturator lymph node showing infiltration by metastatic adenocarcinoma (H&E stain, 20x magnification).

Table 1: Clinicopathological features of reported cases of villoglandular papillary adenocarcinoma with lymph node metastasis

Case	Author	Age	Clinical presentation	Stage	LVI	Lymph node metastasis	Mitotic figure count	Treatment	Follow up	Outcome
1	Kaku T et al 1997 (2 cases)	54	Abnormal uterine bleeding	IIB	Positive	Positive (Right obturator lymph Node)	-	RAH with ERT	46 months	DOD
2		33	Abnormal uterine bleeding	IB	Positive	Positive (Left external iliac and left obturator lymph node)	-	RAH with ERT	10 months	NED
3	Utsugi K et al 2002	48	Genital bleeding and vaginal discharge	IIB	Positive	Positive (Right external iliac lymph node, left external iliac lymph nodes, and obturator lymph nodes)	105/10 HPF	Wertheim hysterectomy with pelvic lymphadenectomy and bilateral adenectomy with whole pelvic irradiation	17 years	NED
4-5	Khunamornpong S et al 2001 (2 cases)	-	-	IB-IIA	Positive	Positive	-	RAH with ERT	21-144 months	NED
6	Garcea A et al 2003	29	Postcoital bleed	IIB	Negative	Positive (Right obturator lymph node)	-	RAH with ERT	34 months	NED
7	Present case	45	Abdominal pain	IB	Negative	Positive (Right obturator lymph node)	90/10 HPF	Bilateral salpingoophrectomy and lymphadenectomy with ERT and chemotherapy	7 months	Died of Chest Infection

DOD - Died of disease, NED - No evidence of disease, RAH - Radical hysterectomy, ERT - External radiation therapy, LVI - Lymphovascular invasion, HPF - High power field

to 54 years (mean, 41 years). The clinical presentation includes abnormal uterine bleeding (43%), vaginal discharge (14%), postcoital bleeding (14%) and abdominal pain (14%). Five cases had lymphovascular invasion (71%). The obturator lymph node (100%) is the commonest site of metastasis, with greater propensity towards the right side, followed by the external iliac lymph node (40%). The mitotic figure count reported by Utsugi K et al (2002) and the present case were 105/10HPF and 90/10HPF, respectively. All cases were followed up between seven months to 17 years, of which two died (28.6%), one due to the disease and the other because of chest infection.

DISCUSSION

Villoglandular papillary adenocarcinoma is a distinct entity and rare histological variant of cervical adenocarcinoma, which is believed to have a favourable prognosis and predominantly develops in young women with oral contraceptive use (Young RH et al 1989, Jones MW et al 1993). Young and Scully (1989) described a case of oral contraceptive use in their 13 cases of VGPA. Later, Jones et al (1993) demonstrated a statistically significant difference in the incidence of oral contraceptive use in five of the 24 VGPA. Other published series showed no consistent association between oral contraceptive use and villoglandular papillary adenocarcinoma, hence it remains debatable (Garcea A et al 1988).

The three important histopathological features of VGPA are 1) an exophytic growth pattern, 2) papillary architecture and 3) mild to moderate nuclear atypia. The epithelium can be a mixture of endometrial, endocervical and intestinal differentiation. The differential diagnosis of VGPA includes 1) serous papillary adenocarcinoma in which complex papillae lined by markedly atypical nuclei with high mitotic activity are present, 2) endocervical adenocarcinoma with a minor villoglandular

component, and 3) minimal deviation adenocarcinoma, with a diffusely infiltrative growth pattern and absence of cytologic atypia.

Young and Scully (1989) mentioned that VGPA should be reserved for those tumours composed exclusively or almost exclusively of villoglandular papillary pattern (Young RH et al 1989). Various authors have reported the association of other patterns, for example squamous cell carcinoma (Kaku T et al 1997), small cell carcinoma (Van Nagell JR et al 1988) and adenocarcinoma in situ (Jones MW et al 1993). Hence, a thorough search for coexistence of a different malignancy such as squamous cell carcinoma, small cell carcinoma, etc. is mandatory.

In most malignancies, the tumour size, depth of invasion, lymphovascular invasion and lymph node metastasis are considered histological risk factors for recurrence. Utsugi K et al (2002) tried to determine the relationship between mitotic figure counts with incidence of lymph node metastasis. They found a significant difference in mitotic figure count of 105/10HPF in their patient with lymph node metastasis, as compared with 12 other patients without lymph node metastasis where the median mitotic figure count was 28/10 HPF (range between 4-70/10 HPF) (Utsugi K et al 2002). The mitotic figure count for our patient is 90/10 HPF, which supports this observation.

Various reports recommend conservative management, i.e. a cone biopsy, after a careful review of the histopathological findings (Young RH et al 1989, Jones MW et al 1993). We emphasise that a careful search for any lymphovascular invasion, coexistence of a different tumour such as squamous cell carcinoma or small cell carcinoma and mitotic figure count be carried out, and when present, they should be included in the histopathological report. These should be considered as poor prognostic factors for VGPA.

All the seven VGPA cases with lymph

node metastases received radiotherapy and after a range of follow up of seven months to 17 years, six of the seven cases (86%) showed no evidence of disease. Although the number of cases is too small to give any conclusive comments, VGPA with lymph node metastases seems to have a better outcome after radical hysterectomy followed by radiotherapy and chemotherapy.

REFERENCES

- Costa MJ, McIlnay KR, Trelford J. Cervical carcinoma with glandular differentiation: Histological evaluation predicts disease recurrence in clinical stage I or II patients. *Human Pathology* 1995; 26:829-837.
- Garcea A, Nunns D, Ireland D, Brown L. A case of villoglandular papillary adenocarcinoma of the cervix with lymph node metastasis. *BJOG* 2003; 110:627-629.
- Hopson L, Jones MA, Boyce CR, Tarraza HM. Papillary villoglandular carcinoma of the cervix. *Gynecology Oncology* 1990; 39:221-224.
- Jones MW, Silverberg SG, and Kurman RJ. Well-differentiated villoglandular adenocarcinoma of the uterine cervix: A clinicopathological study of 24 cases. *Int J Gynecol Pathol* 1993; 12:1-7.
- Kaku T, Kamura T, Shigematsu T. Adenocarcinoma of the cervix with predominantly villoglandular papillary growth pattern. *Gynecology Oncology* 1997; 64:147-152.
- Khunamornpong S, Maleemonkol S, Siriaunkagul S, Pantusart A. Well-differentiated villoglandular adenocarcinoma of the uterine cervix: a report of 15 cases including two with lymph node metastasis. *J Med Assoc Thai* 2001; 84(6):882-888.
- Novotny DB, Ferlisi P. Villoglandular adenocarcinoma of the cervix: cytologic presentation. *Diagnostic Cytopathology* 1997; 17:383-387.
- Reed W, Abeler VM, Trope CG. Villoglandular adenocarcinoma of the uterine cervix. *Tidsskr Nor Loegeforen* 1993; 113:2569-2571.
- Stanley-Christian H, Heim BK, Hines JF, Hall KL, Willet GD, Bames WA. Villoglandular adenocarcinoma of the cervix: a report of the three cases and review of the literature. *Gynecology Oncology* 1997; 66:327-330.
- Utsugi K, Shimizu Y, Akiyama F, Hasumi K. Villoglandular papillary adenocarcinoma of the uterine cervix with bulky lymph node metastases. *Euro J Obstet Gynecol Reprod Biol* 2002; 105:186-188.
- Van Nagell JR, Powell DE, Gallion HH, Elliott DG, Donaldson ES, Carpenter AE, Higgins RV, Kryscio R and Pavlik EJ. Small cell carcinoma of the uterine cervix. *Cancer* 1988; 62:1586-1593.
- Young RH, Scully RE. Invasive adenocarcinoma and related tumors of the uterine cervix. *Seminal Diagnostic Pathology* 1990; 7:205-207.
- Young RH, Scully RE. Villoglandular papillary adenocarcinoma of the uterine cervix: A clinicopathologic analysis of 13 cases. *Cancer* 1989; 63:1773-1779.