

CASE REPORT

Foreign Body Aspiration in Adult: Removing Aspirated Foreign Body using Flexible Bronchoscopy in Emergency Department

ISMAIL MS, FAREENA Z

Department of Emergency Medicine, Faculty of Medicine, Universiti Kebangsaan Malaysia Medical Centre, Jalan Yaacob Latif, Bandar Tun Razak, 56000 Cheras, Kuala Lumpur, Malaysia.

ABSTRAK

Aspirasi bendasing boleh mengancam nyawa. Presentasi yang tidak tipikal dan kekurangan pengimejan diagnostik, telah membuatkan kecurigaan klinikal adalah penting. Kami ingin melaporkan kes aspirasi bendasing dalam seorang dewasa yang hadir ke Jabatan Kecemasan dalam keadaan yang tidak sedarkan diri. Lelaki berusia 31 tahun yang lumpuh disebabkan oleh keretakan 'cervical 7th fracture' dihantar ke Jabatan Kecemasan selepas tidak sedarkan diri dan mengalami penurunan peratusan oksigen disebabkan oleh aspirasi bendasing. Ini adalah kes atipikal aspirasi bendasing pada pesakit yang berjaya didiagnosis dan dirawat menggunakan bronkoskopi fleksibel di Jabatan Kecemasan. Aspirasi bendasing pada orang dewasa sering diabaikan terutama jika ia tidak menyebabkan sesak nafas. Indeks kecurigaan yang tinggi diperlukan terutamanya untuk pesakit berisiko tinggi yang menunjukkan simptom atipikal. Bronkoskopi fleksibel dan 'rigid' adalah kaedah diagnosis dan rawatan pesakit yang disyaki aspirasi bendasing. Kesimpulannya, pelbagai jenis penemuan klinikal aspirasi bendasing yang tidak aspirasi dalam saluran udara pada orang dewasa telah dipaparkan. Faktor diagnostik yang paling penting adalah indeks klinikal curiga yang tinggi. Walaupun bronkoskopi 'rigid' terus menjadi instrumen pilihan untuk menghilangkan bendasing yang tidak aspirasi di saluran udara orang dewasa, tetapi bronkoskop optik gentian optik juga boleh digunakan dalam keadaan yang tertentu.

Kata kunci: aspirasi bendasing, bronkoskopi, fiber optik, jabatan kecemasan

ABSTRACT

Foreign body aspiration (FBA) possess a catastrophic life-threatening event. Faint

Address for correspondence and reprint requests: Fareena Zahari. Department of Emergency Medicine, Faculty of Medicine, Universiti Kebangsaan Malaysia Medical Centre, Jalan Yaacob Latif, Bandar Tun Razak, 56000 Cheras, Kuala Lumpur, Malaysia. Tel: +6016-2067480 Email: fareenazahari@yahoo.com

presentation with a sparsity of radiological findings in adult FBA made the clinical suspicion extremely crucial. We describe a case of FBA in an adult, presenting with loss of consciousness and oxygen desaturation. A 31-year-old male who was tetraplegic with underlying seventh cervical vertebral fracture, presented to the Emergency Department after a sudden loss of consciousness and acute oxygen desaturation secondary to aspiration of a foreign body. This was the case of atypical presentation of FBA in a patient diagnosed with a flexible bronchoscope in the Emergency Department. FBA often goes unnoticed in adults, particularly if it does not cause asphyxiation. Clinician utmost index of suspicion is needed especially for high-risk patients presenting with atypical symptoms. Flexible and rigid bronchoscopy are the cornerstone of both diagnosis and treatment of patients with suspected FBA. In adults, the clinical presentation of non-asphyxiating foreign bodies in the airway is variable. High clinical index of suspicion is the most valuable diagnostic factor. Although rigid bronchoscopy continues to be the preferred instrument for removal of non-asphyxiating foreign bodies in the airways in most hospitals, a flexible fibre optic bronchoscope is also capable in providing therapeutic option is selected at times.

Keywords: bronchoscope, emergency department, fibre optic, foreign body aspiration

INTRODUCTION

Foreign body aspiration (FBA) possess a catastrophic life-threatening event. Although commonly seen in children, FBA cases involving adults are occasionally encountered (Kam et al. 2013). In adults, risk factors include drug or alcohol intoxication, impairment in the swallowing reflex, neurological impairment, loss of consciousness due to trauma, or anaesthesia (Boyd et al. 2009). Faint presentation with a sparsity of radiological findings in adult FBA has made clinical suspicion extremely crucial. Direct visualisation of the foreign body by bronchoscopy is mandated for definitive diagnosis and appropriate treatment (Sehgal et al. 2015). We discuss a case of tetraplegic adult presenting with

loss of consciousness and oxygen desaturation.

CASE REPORT

A 31-year-old male, was admitted to a rehabilitation hospital for physiotherapy due to underlying tetraplegia & neurogenic bladder as a result of seventh cervical vertebra fracture. He was last seen well around 1 am at the rehabilitation hospital and was talking to his wife, while eating chips. There was no history of choking or coughing as noted by his wife. At 3 am, he was found to be unconscious by the rehabilitation nurse with no spontaneous breathing but the pulse was present.

The initial vital signs included blood pressure 63/30 mmHg, heart rate 36

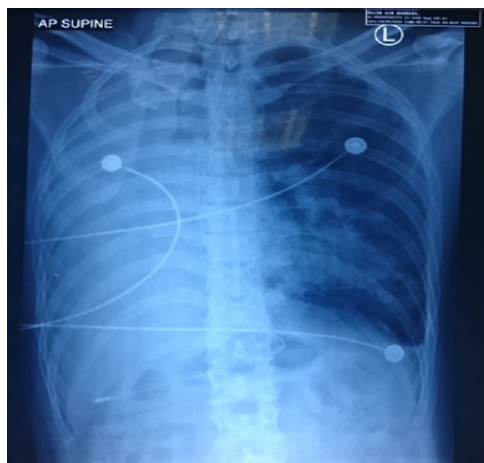


Figure 1: CXR post-intubation before any bronchoscopy and suctioning intervention. Right lung atelectasis and shifting of trachea towards right lung noted.

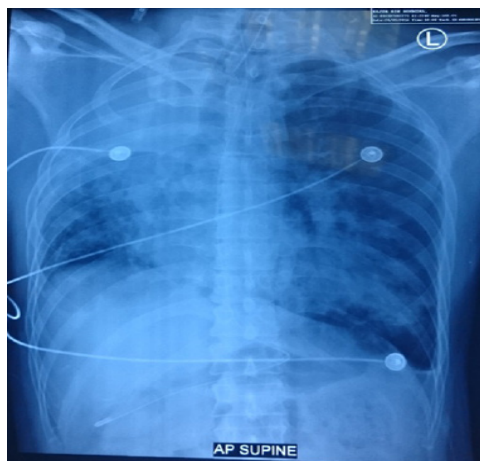


Figure 2: CXR after suctioning using flexible bronchoscope in Emergency Department. Partial resolution of atelectasis seen over the right lung.

bpm, and oxygen saturation (SpO_2) 36% (under room air). Patient was resuscitated with fluids and was put on inotrope IVI dopamine 5 mcg/kg/min. Intubation was attempted but failed due to stiff neck. Bag-valve-mask ventilation was performed and saturation was able to be maintained at 100%. He was immediately transferred to a tertiary referral hospital for further management. The referral to the tertiary hospital was made prior transfer, so the receiving team was ready to receive the patient.

In the tertiary referral hospital immediate resuscitation was commenced. He was intubated. However, it was noted that the saturation decreased progressively until it reached the lowest of 76% despite on FiO_2 of 1.0. The chest X-ray (CXR) showed right lung atelectasis with the trachea deviated to the right and an hyperinflated left lung (Figure 1). Arterial blood gas (ABG)

showed respiratory acidosis with type 2 respiratory failure, pH 7.1, pO_2 41 mmHg, HCO_3^- 28.9 mmol/L, BE -3.7 and pCO_2 95 mmHg.

Suspicion for foreign body aspiration was based on history of food ingestion in the patient with impaired swallowing reflex, in addition to an acute oxygen desaturation and radiological finding on CXR (Figure 1) led to a decision for diagnostic bronchoscopy using flexible fibre optic by the emergency physician in the ED.

Flexible bronchoscopy (FBr) revealed a thick mucus plug at the right main bronchus. Suction was done through a working channel of the fibre optic bronchoscope. However, there was a limitation on suctioning and lavage that could be achieved through the flexible bronchoscope. CXR showed some improvement after the FBr but was inadequate (Figure 2).

Immediate referral to a respirologist was made for a proper bronchoscopy

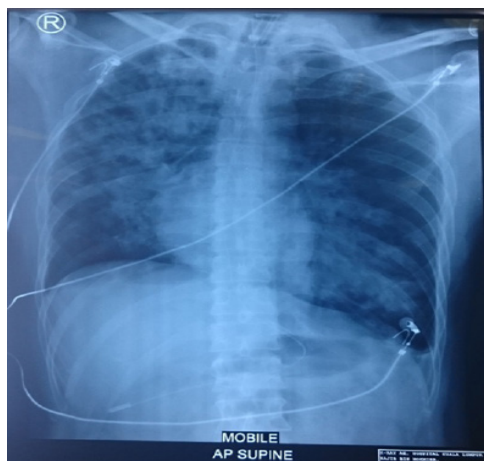


Figure 3: CXR after bronchoalveolar lavage using rigid bronchoscope by the respiratory physician. Resolution of atelectasis over the right lung.

with a rigid bronchoscope. Rigid bronchoscopy found a thick mucus plug at the right upper lobe and was removed with lavage and washing. However, the left lung was normal. The impression of this was a case of aspiration, secondary to foreign body.

Rapid improvement was seen after suctioning and bronchoalveolar lavage. SpO₂ increased from 76% to 100% and lowering of FiO₂ was

made possible (Table 1). Carbon dioxide (CO₂) retention resolved and respiratory acidosis was neutralized. Patient ABG improved to pH 7.31, pO₂ 175 mmHg, pCO₂ 42 mmHg (with FiO₂ 0.5). Improvement of CXR could be seen, as well (Figure 3). The patient was admitted to the Intensive Care Unit (ICU), extubated on day-3 of admission and subsequently discharges well.

DISCUSSION

FBA is rarely seen in adults compared to children, with about 80% of FBA cases occurring in children younger than 15 years (Oke et al. 2015). In adults, especially if there is no history of asphyxiation, FBA often goes unnoticed as a potential cause of airway obstruction. Adults with risk factors such as drug abuse, neuromuscular conditions, mental retardation and alcoholism are inclined to aspiration. However, in adults, accidental aspiration without the above-mentioned risk factors have been described (Berzlanovich et al. 2005). Commonly aspirated foreign

Table 1: Patient's ABG result pre and post intervention done by bronchoscopy with FiO₂ setting on ventilator. Improvement in oxygenation can be seen after intervention with bronchoscopy started

Time	Normal Value	7 am	8 am	10 am	12 pm	2 pm	4 pm	6 pm	9 pm
pH	7.35 - 7.45	7.24	7.273	7.1	7.125	7.249	7.26	7.269	7.311
pO ₂ (mmHg)	80-100	93.1	41	94	180.7	95.4	187.2	163.7	175.8
pCO ₂ (mmHg)	35 - 45	36.9	61.6	95.3	87	57.4	50.1	47	42.9
HCO ₃ (mmHg)	22 - 30	23.4	27.8	28.9	28	24.5	22.3	21.2	22
BE (mmol/L)	(-5) - (+5)	-0.4	-0.4	-3.7	-3.8	-3.7	-5.3	-4.9	-4.2
FiO ₂		1.0	1.0	1.0	1.0	0.8	0.7	0.6	0.5
		Pre-bronchoscopy				Post-bronchoscopy			

bodies in adults are food and broken fragments of teeth. In adults, most of the foreign bodies (FBs) are embedded in the right bronchial tree, whereas no compelling difference was appreciated between left and right bronchial tree in children. Unlike in children, FBs lodged in the proximal airways are seen in less than half of adults (Baharloo et al. 1999). Whatever be the cause of FBA, the ability to maintain a patient airway is of utmost importance.

In the absence of symptoms of asphyxiation, we need to correlate with clinical findings. In cases with acute desaturation, loss of consciousness with CXR of lung atelectasis, mediastinal shift, hyperinflated lung and pneumonia, we should have a high index of suspicion for FBA. (Boufersaoui et al. 2013). Pulmonary abscesses and bronchiectasis are late manifestations of a retained FB in the airway (Denney et al. 1968). If FBA is known to have occurred or is strongly suspected, bronchoscopy is the procedure of choice to identify and remove the object.

Gustav Killian, an otolaryngologist, introduced the usage of bronchoscopy for the removal of FB in 1897 (Prowse & Makura 2012). In 1968 Shigeto Ikeda developed FBr for easier handling and manoeuvring (Niwa et al. 2009). Zavala and Rhodes (1974) performed animal studies that showed FBr could be used to recover various FBs by using the bronchoscope grasping forceps (Zavala & Rhodes 1974). Thereafter, FBr has attained prevalence over rigid bronchoscopy. For initial diagnosis of FB in adults, FBr is considered as the diagnostic test of choice. The

advantages of FBr over the rigid bronchoscopy are better viewing of the smaller peripheral airway with smooth handling and can be performed under local anaesthesia. It can be done in c-spine and pharyngeal deformities like this case. It is also comparatively safer and easier procedure in skilled-hands (Rafanan & Mehta 2001).

Rigid bronchoscopy foreign body retrieval was acquired in 43 out of 44 patients, along with 6 of 7 patients in whom, fibre optic bronchoscopy recovery had failed (Limper & Prakash 1990). The success rate was 60% among 23 patients, in whom a fibre optic bronchoscopy recovery was attempted (Limper & Prakash 1990). They discovered that flexible fibre optic bronchoscopy was notably beneficial in patients with foreign bodies too distal in the airways for access using a rigid bronchoscope, and in whom severe cervicofacial trauma hinders hyperextension of the neck that was essential for rigid bronchoscopy examination (Limper & Prakash 1990).

CONCLUSION

There were few key-points that can be taken away from this case. First, in the event of inability to intubate, the most important thing, is the ability to maintain oxygenation. In emergency situation, where intubation attempts fail, ability to maintain oxygenation can buy time for transferring the patient to the more experience handler. Second, there is importance of communication between two teams. The rehabilitation hospital team alerted the tertiary team regarding the transfer of

difficult intubation patient. This vital information led to preparation of equipment and experienced personnel at the receiving hospital. Third, the presence of emergency physician who had high index of suspicion and knew how to manoeuvre a flexible bronchoscope led to early diagnosis and urgent referral to the respirologist for specific management. This resulted in swift recovery of the patient. Finally, the clinical presentation of non-asphyxiating foreign bodies in the airway is variable. High clinical index of suspicion is the most valuable diagnostic factor. Although rigid bronchoscopy continues to be the preferred instrument for removal of non-asphyxiating foreign bodies in the airways in most hospitals, a flexible fibre optic bronchoscope provides a valuable therapeutic option in selected conditions and could be really helpful in the ED.

REFERENCES

- Baharloo, F., Veyckemans, F., Francis, C., Bietlot, M. P., Rodenstein, D.O. 1999. Tracheobronchial foreign bodies: presentation and management in children and adults. *Chest* **115**(5): 1357-62.
- Berzlanovich, A.M., Fazyen-Dorner, B., Waldhoer, T., Fasching, P., Keil, W. 2005. Foreign body asphyxia: a preventable cause of death in the elderly. *Am J Prev Med* **28**(1): 65-9.
- Boufersaoui, A., Smati, L., Benhalla, K.N., Boukari, R., Smail, S., Anik, K., Aouameur, R., Chaouche, H., Bagriche, M. 2013. Foreign body aspiration in children: experience from 2624 patients. *Int J Pediatr Otorhinolaryngol* **77**(10): 1683-8.
- Boyd, M., Chatterjee, A., Chiles, C., Chin, R.J. 2009. Tracheobronchial foreign body aspiration in adults. *South Med J* **102**(2): 171-4.
- Denney, M.K., Berkas, E.M., Snider, T.H., Nedwicki, E.G. 1968. Foreign body bronchiectasis. *Dis Chest* **53**(5): 613-6.
- Kam, J.C., Doraiswamy, V., Dieguez, J.F., Dabu, J., Cholankeril, M., Govind, M., Miller, R., Adelman, M. 2013. Foreign body aspiration presenting with asthma-like symptoms. *Case Rep Med* **2013**: 317104.
- Limper, A.H., Prakash, U.B. 1990. Tracheobronchial foreign bodies in adults. *Ann Intern Med* **112**(8): 604-9.
- Niwa, H., Tanahashi, M., Kondo, T., Ohsaki, Y., Okada, Y., Sato, S., Suzuki, E., Senba, H., Fujino, S., Miyazawa, T., Kobayashi, K. 2009. Bronchoscopy in Japan: a survey by the Japan Society for Respiratory Endoscopy in 2006. *Respirology* **14**(2): 282-9.
- Oke, V., Vadde, R., Munigikar, P., Bhattarai, B., Agu, C., Basunia, R., Salhan, D., Enriquez, D., Quist, J., Schmidt, F. 2015. Use of flexible bronchoscopy in an adult for removal of an aspirated foreign body at a community hospital. *J Community Hosp Intern Med Perspect* **5**(5): 10.3402/jchimp.v5.28589
- Prowse, S.J., Makura, Z. 2012. Gustav Killian: beyond his dehiscence. *J Laryngol Otol* **126**(11): 1164-8.
- Rafanan, A.L., Mehta, A.C. 2001. Adult airway foreign body removal. What's new? *Clin Chest Med* **22**(2): 319-30.
- Sehgal, I.S., Dhooria, S., Ram, B., Singh, N., Aggarwal, A.N., Gupta, D., Behera, D., Agarwal, R. 2015. Foreign body inhalation in the adult population: experience of 25,998 bronchoscopies and systematic review of the literature. *Respir Care* **60**(10): 1438-48.
- Zavala, D.C., Rhodes, M.L. 1974. Experimental removal of foreign bodies by fiberoptic bronchoscopy. *Am Rev Respir Dis* **110**(3): 357-60.

Received: 24 Jul 2019

Accepted: 5 Feb 2020