

**CASE REPORT**

## A Case of Missed Giant Bullae Emphysema Diagnosed as Pneumothorax

ONG SF, NIK AZLAN NM

*Department of Emergency Medicine, Faculty of Medicine, Universiti Kebangsaan Malaysia Medical Centre, Jalan Yaacob Latif, Bandar Tun Razak, 56000 Cheras, Kuala Lumpur, Malaysia.*

### ABSTRAK

*Kami melaporkan kes emfeseema bullous gergasi yang disalah diagnos sebagai pneumotoraks. Seorang lelaki perokok kronik berusia 18 tahun hadir dengan sakit dada sebelah kanan dan sesak nafas. Kadar pernafasan adalah 35/min, tekanan darah 139/90 mmHg, kadar nadi 80/min dan SpO<sub>2</sub> pada udara bilik adalah 98%. X-ray dada ditafsir sebagai pneumotoraks spontan. Aspirasi jarum telah dijalankan tetapi keadaan pesakit merosot. Kemudian tiub dada torakostomi dilakukan. Selepas itu, berlaku pendarahan di dalam toraks. Keadaan pesakit merosot. CT toraks telah dilakukan dengan segera dan menunjukkan bahawa terdapat hemopneumotoraks dengan banyak bullae. Pesakit telah digegaskan ke bilik pembedahan untuk torakostomi. Pengajaran yang boleh dipelajari daripada kes ini adalah bahawa bullae emfeseema gergasi boleh menyamar sebagai pneumotoraks dan perhatian lebih perlu sebelum torakosintesis dilaksanakan.*

*Kata kunci: emfeseema, hemopneumotoraks, torakostomi, toraks*

### ABSTRACT

We report a case of a giant bullous emphysema misdiagnosed as a pneumothorax. A 18-year-old chronic smoker presented with right sided chest pain and dyspnoea. Initial respiratory rate was 35 /min, blood pressure was 136/90 mmHg, heart rate 80/min and SpO<sub>2</sub> was 98% on room air. Clinical examination revealed reduced right air entry and left trachea deviation. Chest X-ray helped to arrive at a diagnosis of pneumothorax. Needle aspiration was then performed followed by a chest tube thoracostomy because of no improvement. Massive amount of blood was drained and patient deteriorated further. CT thorax revealed a right haemopneumothorax with multiple bullae. Patient was rushed to OT for emergency thoracotomy for stapling of the ruptured bullae. Giant bullous emphysema can mimic pneumothorax and physician must be vigilant if draining a suspected pneumothorax.

**Address for correspondence and reprint requests:** Nik Azlan Nik Muhamad, Department of Emergency Medicine, Faculty of Medicine, Universiti Kebangsaan Malaysia Medical Centre, Jalan Yaacob Latif, Bandar Tun Razak, 56000 Cheras, Kuala Lumpur, Malaysia. Tel: +603-91455703 Fax: +603-91456577 E-mail: [nikazlanmuhamad@hotmail.com](mailto:nikazlanmuhamad@hotmail.com)

Keywords: emphysema, haemopneumothorax, thoracostomy, thorax

---

## INTRODUCTION

Diagnosis of primary spontaneous pneumothorax is made in young patients with no underlying lung disease. However, there is increasing incidence of bullous lung disease particularly among smokers. A giant bulla can mimic a pneumothorax, hence differentiation between the two is a challenge (Isha et al. 2016). Chest tube insertion in a tension pneumothorax is life-saving. However, chest tube insertion into giant bullae can be harmful. Physicians are sometimes reluctant to request for CT thorax that would differentiate these two due to time and cost restraints.

## CASE REPORT

An 18-year-old, thin built gentleman presented with sudden onset right sided chest pain while playing video game arcade. Chest pain was aggravated with movement and deep inspiration. This was associated with shortness of breath. The patient was a chronic smoker and had symptoms of upper respiratory tract infection 3 days prior. No other history was significant.

Generally, he appeared tachypnoeic with the respiratory rate of 35 breaths/min. No wheeze or stridor was heard. There was no cyanosis. Blood pressure was 136/90 mmHg, heart rate was 80 beats/min and oxygen saturation on room air was 98%. Lungs examination revealed reduced air entry on the right and hyper-resonant percussion on the

left. Trachea was slightly deviated to the left. Chest radiograph showed a right pneumothorax (Figure 1a). A total of 2500 ml air was aspirated via needle thoracocentesis. The procedure was stopped as soon as the patient started to cough. Chest radiograph was done post-procedure to assess resolution.

Post-procedural chest radiograph revealed expansion of right pneumothorax (Figure 1b). In response to this, chest tube was inserted. Chest radiograph was taken post-chest tube insertion and there was substantial right lung haziness (Figure 2). The impression at that moment was re-expansion pulmonary oedema. One hour after chest tube insertion, dyspnoea started to worsen. Mild pallor was noted. Chest tube drained a total 1.2 litre of blood. Patient developed tachycardia with the heart rate of 120 beats/min, nevertheless the blood pressure and the saturation was stable. At this point Class II hemorrhagic shock was suspected.

CT thorax showed right haemopneumothorax with contralateral mediastinal shift. The right lung was collapsed. There were multiple bullae seen within the collapsed right upper, middle and lower middle lobes, as well as the left apical segment of left upper lobe, largest seen at the right upper lobe measuring 1.6 x 1.7 x 2.3 cm (Anterior-Posterior x Width x Cranial-Caudal). The impression from the CT thorax was massive right haemopneumothorax with increasing attenuation value of the pleural fluid

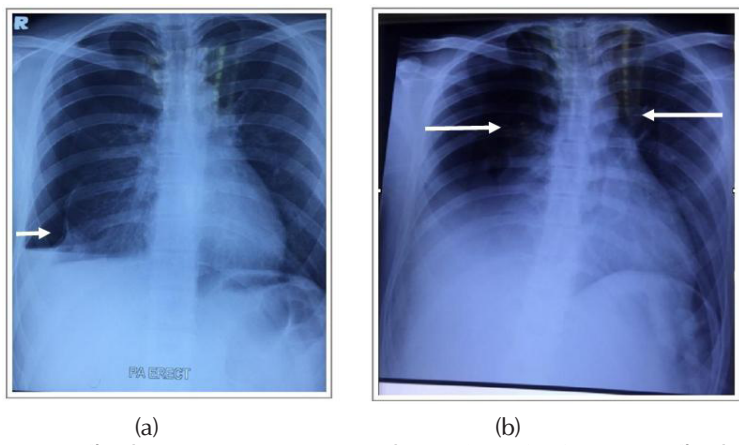


Figure 1: a) Pre-needle thoracocentesis, pneumothorax (arrow), b) post-needle thoracocentesis, expansion of pneumothorax (arrow)

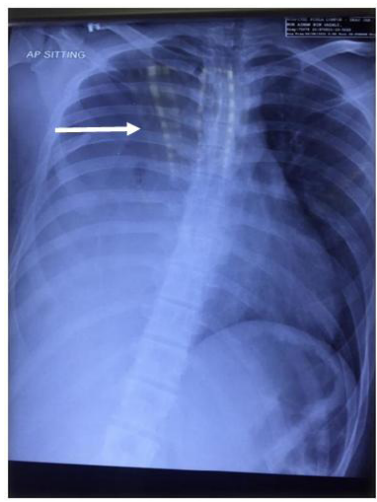


Figure 2: Post-chest tube insertion

upon contrast administration suggestive of slow oozing into the pleural cavity.

Patient was pushed to the operation theatre for emergency thoracotomy. Intra-operative findings were collapsed right lung with multiple bullae on the upper lobe. There were adhesion bands between apex chest wall and upper lobe. Haemorrhage was secured from one of the ruptured bullae of upper lobe adjacent to the chest wall. Total blood removed was 1250 ml.

Stapler bullectomy was done and two drains were inserted at the apex and diaphragm. Patient was later admitted to ICU and finally discharged home well.

**DISCUSSION**

A bullae is defined as a distended air space in the lung more than one centimeter in diameter. A giant bullae is a bullae that occupies more than 30% of a hemithorax. Giant bullae develops as a complication of cigarette smoking. However, other causes are idiopathic. Patients with giant bullae can have no symptoms. Acute bleeding into the bulla will present with hemoptysis. On physical examinations patients may have barrel-shaped chest, decreased breath sounds, and hyper-resonant percussion. This makes it more difficult to distinguish from a pneumothorax.

Giant bullae can be identified on plain chest radiograph, and it is always confused with pneumothorax. The characteristics of the pleural line on the plain chest radiograph can aid in

differentiating a pneumothorax from a giant, thin-walled bulla. In large bulla, the pleural line usually concave (open angle) compared to the lateral chest wall, while in pneumothorax, the pleural line is usually convex (narrow angle) compared to the lateral chest wall. On CT thorax, majority of the giant bullae are subpleural and located at the upper lobes.

A primary spontaneous pneumothorax (PSP) is a pneumothorax that occurs without a precipitating event in a person that with no known underlying lung disease. However, majority of patients with PSP have underlying undiagnosed lung disease, and the rupture of the subpleural bleb was the cause of the pneumothorax (Bense et al. 1993). Predisposing factors to PSP include smoking, Marfan syndrome, family history, thoracic endometriosis, and homocystinuria. Cigarette smoking is an important risk factor for PSP. The postulated pathophysiology is that cigarette smoke induces the influx of macrophages and neutrophils that leads to degradation of the lung elastic fibres. The degradation results an imbalance in the oxidant-antioxidant and protease-antiprotease systems. Small airways obstruction secondary to the inflammation increases alveolar pressure, thus causing an air leak into the lung interstitium. Subsequently, the air moves to the hilum, resulting in pneumomediastinum and causing rupture of the mediastinal pleura when the mediastinal pressure increases and results in pneumothorax (Ohata & Suzuki 1980).

The use of lung ultrasound is important in the diagnosis of pneumothorax in unstable patients. However, it was reported that giant bullae can mimic ultrasonic findings of a pneumothorax with giving an absent sliding sign and a 'bleb point' that mimics a lung point (Gelabert & Nelson 2015).

## CONCLUSION

Giant bullae can mimic a pneumothorax. Plain radiograph alone is inadequate to distinguish a giant bullae from a pneumothorax. This is imperative because the management is different. If the patient is haemodynamically stable, and underlying lung disease cannot be ruled out, it is advised to proceed with CT thorax to exclude bullous lung disease.

## REFERENCES

- Bense, L., Lewander, R., Eklund, G., Hedenstierna, G., Wiman, L.G. 1993. Nonsmoking, non-alpha 1-antitrypsin deficiency-induced emphysema in non-smokers with healed spontaneous pneumothorax identified by computed tomography of the lungs. *Chest* 103(2): 433-8.
- Gelabert, C., Nelson, M., 2015. Bleb point: mimicker of pneumothorax in bullous lung disease. *West J Emerg Med* 16(3): 447-9.
- Isha, G., Agrawal, K.C., Gopal, P., Srikant A., Narendra U., 2016. Giant bulla or tension pneumothorax: diagnostic dilemma in emergency. *Chest* 150(4 (supp)): 929A.
- Ohata, M., Suzuki, H., 1980. Pathogenesis of spontaneous pneumothorax with special reference to the ultrastructure of emphysematous bullae. *Chest* 77(6): 771-6.

Received: 19 May 2016

Accepted: 9 May 2017